








ID Number	ID Photo	Signalment	Individual Scene Findings	Pertinent Exam Findings	Diagnostics	Treatments
2038-1A-001		<p>Young adult, white, male Samoyed-type dog</p>	<p>Co-housed in wood and chain-link enclosure within a barn. Straw on floor with fecal debris. The barn smelled strongly of ammonia. No access to food or water.</p>	<p>This dog is thin at a body condition score of 3/9 on the Purina scale. Dental grade of 1/4 with very mild plaque on carnassial teeth. Mild matting particularly on hind quarters. Dull coat. Exaggerated response to tactile stimuli.</p>	<p>PCV/TS- 40%/7.8, 4DX-Negative and Fecal pending.</p>	<p>Vaccinated (Rabies, DAPP, Bordetella), dewormed, started on flea/tick preventative and heartworm preventative. Recommend increasing nutritional plane and recheck weight/BCS in two weeks. Recommend further behavioral evaluation for possible pharmacologic intervention. Grooming need.</p>



Plaintiff's Exhibit 23



<p>2038-1A-002</p>		<p>Young adult, white, male Samoyed-type dog</p>	<p>Co-housed in wood and chain-link enclosure within a barn. Straw on floor with fecal debris. The barn smelled strongly of ammonia. No access to food or water.</p>	<p>This dog is thin at a body condition score of 3/9 on the Purina scale. Dental grade of 1/4 with mild plaque on carnassial teeth. Unilateral cryptorchid, left testicle present right is not palpated inguinally. Non-painful malformation of distal tail, last two vertebrae are kinked towards the left. Dry coat, mild amount of plant debris throughout coat; multiple 1-2 inch matts on hind quarters and multiple small matts below base of ears bilaterally.</p>	<p>PCV/TS- 33%/7.9, 4DX- Negative and Fecal pending.</p>	<p>Vaccinated (Rabies, DAPP, Bordetella), dewormed, started on flea/tick preventative and heartworm preventative. Recommend grooming and cryptorchid surgery. Recheck weight in two weeks, increase nutritional plane.</p>
--------------------	---	--	--	---	--	--




<p>2038-1A-003</p>		<p>Young adult, white, male Samoyed-type dog</p>	<p>Co-housed in wood and chain-link enclosure within a barn. Straw on floor with fecal debris. The barn smelled strongly of ammonia. No access to food or water.</p>	<p>This dog is lean at a body condition score of 4/9 on the Purina scale. Elevated temperature. Thick yellow-green partially dried nasal discharge within nares, bilaterally. Mildly overgrown nails and dry dirty hair coat. Dental grade 1 with very mild plaque on carnassials and hypersalivation.</p>	<p>PCV/TS- 47%/7.7, 4DX-Negative, CBC/Chem, Respiratory PCR and Fecal pending.</p>	<p>Vaccinated (Rabies, DAPP, Bordetella), dewormed, started on flea/tick preventative and heartworm preventative. Recommended nail trim and behavioral evaluation for possible pharmacological intervention.</p>
--------------------	---	--	--	--	--	--



<p>2038-1A-004</p>		<p>Young adult, white, female Samoyed-type dog</p>	<p>Co-housed in wood and chain-link enclosure within a barn. Straw on floor with fecal debris. The barn smelled strongly of ammonia. No access to food or water.</p>	<p>This dog is thin at a body condition score of 3/9 on the Purina scale. Dental grade of 1/4 with mild plaque on carnassial teeth. Yellow green discharge from nares bilaterally. Mild dried dirt on inside of pinnae. Dry hair coat, mild matting of tail and hind quarters, small amount of fecal matter present in feathering of tail, slightly overgrown nails.</p>	<p>PCV/TS- 41%/8.3, 4DX- Negative, Witness pregnancy test- Negative, CBC/Chem, Respiratory PCR and Fecal pending.</p>	<p>Vaccinated (Rabies, DAPP, Bordetella), dewormed, started on flea/tick preventative and heartworm preventative. Elevate nutritional plane - recheck weight in 2 weeks. Monitor coughing and nasal discharge for next two weeks. Recommend behavior evaluation for potential behavior medication and grooming.</p>
<p>2038-1A-005</p>		<p>White, male, Samoyed-type puppy</p>	<p>Co-housed in wood and chain-link enclosure within a barn. Straw on floor with fecal debris. The barn smelled strongly of ammonia. No access to food or water.</p>	<p>This dog is lean at a body condition score of 4/9 on the Purina scale. Very nervous and fearful. Mild matting throughout hair coat.</p>	<p>PCV/TS- 41%/7.2, 4DX- and Fecal pending.</p>	<p>Vaccinated (Rabies, DAPP, Bordetella), dewormed, started on flea/tick preventative and heartworm preventative. Recommend behavior evaluation for possible anxiolytics and bathing and brush out.</p>



<p>2038-1A-006</p>		<p>White, male, Samoyed-type puppy</p>	<p>Co-housed in wood and chain-link enclosure within a barn. Straw on floor with fecal debris. The barn smelled strongly of ammonia. No access to food or water.</p>	<p>This dog is lean at a body condition score of 4/9 on the Purina scale. Very nervous and fearful. Mild matting throughout hair coat and dry paw pads.</p>	<p>PCV/TS- 41%/7.2, 4DX-Negative, CBC/Chem-pending, Fecal pending.</p>	<p>Vaccinated (Rabies, DAPP, Bordetella), dewormed, started on flea/tick preventative and heartworm preventative. Recommend behavior evaluation for possible anxiolytics, bath, brush out and nail trim.</p>
<p>2038-1A-007</p>		<p>White, female, young adult Samoyed-type dog</p>	<p>Co-housed in wood and chain-link enclosure within a barn. Straw on floor with fecal debris. The barn smelled strongly of ammonia. No access to food or water.</p>	<p>This dog is thin to lean at a body condition score of 3.5/9 on the Purina scale. She has mild dental disease and mild matting at base of ears.</p>	<p>PCV/TS- 44%/7.1, 4DX-Negative, Witness pregnancy test-Negative, Fecal pending.</p>	<p>Vaccinated (Rabies, DAPP, Bordetella), dewormed, started on flea/tick preventative and heartworm preventative. Recommend increasing nutritional plane, bath, and brush out.</p>



<p>2038-1A-008</p>		<p>White, male, Samoyed-type puppy</p>	<p>Co-housed in wood and chain-link enclosure within a barn. Straw on floor with fecal debris. The barn smelled strongly of ammonia. No access to food or water.</p>	<p>This puppy is thin at a body condition score of 3/9 on the Purina scale. Collar on puppy measured 21 cm. Neck of puppy measures 25 cm. Tachycardia (HR 200) and pyrexia (103.4°) are observed.</p>	<p>PCV/TS- 40%/6.7, 4DX-too young, Fecal pending.</p>	<p>Vaccinated (Rabies, DAPP, Bordetella), dewormed, started on flea/tick preventative and heartworm preventative. Recommend rechecking pulse and temperature tomorrow, increasing nutritional plane and recheck weight in 1 month.</p>
<p>2038-1A-009</p>		<p>White, male, Samoyed-type puppy</p>	<p>Co-housed in wood and chain-link enclosure within a barn. Straw on floor with fecal debris. The barn smelled strongly of ammonia. No access to food or water.</p>	<p>This puppy is of ideal body condition at a score of 5/9 on the Purina scale. Nails are moderately overgrown and coat is dry and matted.</p>	<p>PCV/TS- 31%/5.8, 4DX-too young, Fecal pending.</p>	<p>Vaccinated (Rabies, DAPP, Bordetella), dewormed, started on flea/tick preventative and heartworm preventative. Recommend bathing, brushing and nail trim.</p>



<p>2038-1A-010</p>		<p>White, male, Samoyed-type puppy</p>	<p>Co-housed in wood and chain-link enclosure within a barn. Straw on floor with fecal debris. The barn smelled strongly of ammonia. No access to food or water.</p>	<p>This puppy is lean at a body condition score of 4/9 on the Purina scale. He is bilaterally cryptorchid with mild matting in coat and mildly overgrown nails.</p>	<p>PCV/TS- 37%/6.7, 4DX- Negative, Fecal pending.</p>	<p>Vaccinated (Rabies, DAPP, Bordetella), dewormed, started on flea/tick preventative and heartworm preventative. Recommend cryptorchid surgery, bath, brush out, and nail trim.</p>
<p>2038-1A-011</p>		<p>White, female, Samoyed-type puppy</p>	<p>Co-housed in wood and chain-link enclosure within a barn. Straw on floor with fecal debris. The barn smelled strongly of ammonia. No access to food or water.</p>	<p>This puppy is thin at a body condition score of 3/9 on the Purina scale. Interdigital debris is present.</p>	<p>PCV/TS- 38%/6.2, 4DX-too young, Fecal pending.</p>	<p>Vaccinated (Rabies, DAPP, Bordetella), dewormed, started on flea/tick preventative and heartworm preventative. Recheck weight in 1 month with proper diet and nutrition.</p>




<p>2038-1A-012</p>		<p>White, male, Samoyed-type puppy</p>	<p>Co-housed in wood and chain-link enclosure within a barn. Straw on floor with fecal debris. The barn smelled strongly of ammonia. No access to food or water.</p>	<p>This puppy is of ideal body condition at a score of 5/9 on the Purina scale. Tachycardia (HR 196), soft stool with gas in intestines, and otic wax and debris are present.</p>	<p>PCV/TS- 32%/6.1, 4DX-too young, Fecal pending.</p>	<p>Vaccinated (Rabies, DAPP, Bordetella), dewormed, started on flea/tick preventative and heartworm preventative. Recheck heart rate.</p>
<p>2038-1A-013</p>		<p>White, female, Samoyed-type puppy</p>	<p>Co-housed in wood and chain-link enclosure within a barn. Straw on floor with fecal debris. The barn smelled strongly of ammonia. No access to food or water.</p>	<p>This puppy is thin at a body condition score of 3/9 on the Purina scale. Tachycardia (HR 180) is observed and dirt/debris is present interdigitally and around mouth.</p>	<p>PCV/TS- 39%/6.2, 4DX-too young, Fecal pending.</p>	<p>Vaccinated (Rabies, DAPP, Bordetella), dewormed, started on flea/tick preventative and heartworm preventative. Reweigh in 1 month with proper diet and nutrition and recheck heart rate.</p>
<p>2038-1A-014</p>		<p>White, female, young adult, Samoyed-type dog</p>	<p>Co-housed in wood and chain-link enclosure within a barn. Straw on floor with fecal debris. The barn smelled strongly of ammonia. No access to food or water.</p>	<p>This dog is of ideal body condition at a score of 5/9 on the Purina scale. She has a pink, tight-fitting collar, dirty coat, and mild dental disease. Mild, waxy otic debris is present.</p>	<p>PCV/TS- 48%/6.5, 4DX-Negative, Witness pregnancy test-Negative, Fecal pending.</p>	<p>Vaccinated (Rabies, DAPP, Bordetella), dewormed, started on flea/tick preventative and heartworm preventative. Recommend bath and brush.</p>



<p>2038-1A-015</p>		<p>White, male, Samoyed-type puppy</p>	<p>Co-housed in wood and chain-link enclosure within a barn. Straw on floor with fecal debris. The barn smelled strongly of ammonia. No access to food or water.</p>	<p>This puppy is lean at a body condition score of 4/9 on the Purina scale. Mild matting and mild dental disease are present.</p>	<p>PCV/TS- 39%/6.5, 4DX-Negative, Fecal pending.</p>	<p>Vaccinated (Rabies, DAPP, Bordetella), dewormed, started on flea/tick preventative and heartworm preventative. Recommend bath and brush.</p>
<p>2038-1A-016</p>		<p>White, female, Samoyed-type puppy</p>	<p>Co-housed in wood and chain-link enclosure within a barn. Straw on floor with fecal debris. The barn smelled strongly of ammonia. No access to food or water.</p>	<p>This puppy is of ideal body condition at a score of 5/9 on the Purina scale. A blue collar is present with circumference of 31.5 cm, neck circumference is 31 cm. Pyrexia (103.0°) is present.</p>	<p>PCV/TS- 42%/7.0, 4DX-too young, Fecal pending.</p>	<p>Vaccinated (Rabies, DAPP, Bordetella), dewormed, started on flea/tick preventative and heartworm preventative. Recommend recheck temperature in am.</p>



<p>2038-1A-017</p>		<p>White, male, Samoyed-type puppy</p>	<p>Co-housed in wood and chain-link enclosure within a barn. Straw on floor with fecal debris. The barn smelled strongly of ammonia. No access to food or water.</p>	<p>This puppy is thin at a body condition score of 3/9 on the Purina scale. He is unilaterally cryptorchid and the fundus of the right eye is difficult to appreciate.</p>	<p>PCV/TS- 37%/6.9, 4DX-too young, Fecal pending.</p>	<p>Vaccinated (Rabies, DAPP, Bordetella), dewormed, started on flea/tick preventative and heartworm preventative. Recommend recheck weight in 1 month with proper nutrition and diet, ophthalmic consultation, and recheck undescended testicle in 2 weeks.</p>
<p>2038-1A-018</p>		<p>White, male, Samoyed-type puppy</p>	<p>Co-housed in wood and chain-link enclosure within a barn. Straw on floor with fecal debris. The barn smelled strongly of ammonia. No access to food or water.</p>	<p>This puppy is very thin at a body condition score of 2/9 on the Purina scale. Pododermatitis and nasal crusting are present. Nails are overgrown.</p>	<p>PCV/TS- 38%/6.9, 4DX- pending, CBC/Chem and Fecal pending.</p>	<p>Vaccinated (Rabies, DAPP, Bordetella), dewormed, started on flea/tick preventative and heartworm preventative. Recommend nail trim, clip and clean feet, and recheck nasal crusting in 2 weeks. Nutritional management and recheck weight.</p>



<p>2038-1A-019</p>		<p>White, female, Samoyed-type puppy</p>	<p>Co-housed in wood and chain-link enclosure within a barn. Straw on floor with fecal debris. The barn smelled strongly of ammonia. No access to food or water.</p>	<p>This puppy is lean at a body condition score of 4/9 on the Purina scale. She has soft stool, mild prognathic maxilla, and pododermatitis and hyperkeratosis of the digital pads.</p>	<p>PCV/TS- 42%/7.8, 4DX-Too young , Fecal pending.</p>	<p>Vaccinated (Rabies, DAPP, Bordetella), dewormed, started on flea/tick preventative and heartworm preventative. Recommend dental recheck in 6 months. Clip and clean areas of debris/feces and recheck in 1 week. Clipped all feet.</p>
<p>2038-1A-020</p>		<p>White, female, Samoyed-type puppy</p>	<p>Co-housed in wood and chain-link enclosure within a barn. Straw on floor with fecal debris. The barn smelled strongly of ammonia. No access to food or water.</p>	<p>This puppy is lean at a body condition score of 4/9 on the Purina scale. Mildly prognathic maxilla not significant. Nasal crusting, vaginal discharge, and pododermatitis are present. Fecal debris is present around rectum. Pyrexia (103.0°) is present.</p>	<p>PCV/TS- 41%/6.5, 4DX-too young , Fecal pending.</p>	<p>Vaccinated (Rabies, DAPP, Bordetella), dewormed, started on flea/tick preventative and heartworm preventative. Recommend clip and clean all feet with recheck in 2 weeks, recheck temp tomorrow, and again in 1 week.</p>



<p>2038-1A-021</p>		<p>White, female, Samoyed-type puppy</p>	<p>Co-housed in wood and chain-link enclosure within a barn. Straw on floor with fecal debris. The barn smelled strongly of ammonia. No access to food or water.</p>	<p>This puppy is lean at a body condition score of 4/9 on the Purina scale. Collar found on neck under fur, tight against skin. Debris in coat. Deciduous teeth present.</p>	<p>PCV/TS- 40%/6.9, 4DX- too young, Fecal pending.</p>	<p>Vaccinated (Rabies, DAPP, Bordetella), dewormed, started on flea/tick preventative and heartworm preventative. Dental recheck in 6 months.</p>
<p>2038-1A-022</p>		<p>White, female, Samoyed-type puppy</p>	<p>Co-housed in wood and chain-link enclosure within a barn. Straw on floor with fecal debris. The barn smelled strongly of ammonia. No access to food or water.</p>	<p>This puppy is lean at a body condition score of 4/9 on the Purina scale. White otic debris in both ears, suspect mites. Mild overbite, pododermatitis and hyperkeratosis are present.</p>	<p>PCV/TS- 32%/5.8, 4DX- too young, Fecal pending. Ear cytology- Normal</p>	<p>Vaccinated (Rabies, DAPP, Bordetella), dewormed, started on flea/tick preventative and heartworm preventative. Recommend ear cleaning and treatment based on results of cytology. Clip and clean all feet. Recheck dental in 6 months.</p>




<p>2038-1A-024</p>		<p>White, male, Samoyed-type puppy</p>	<p>Co-housed in wood and chain-link enclosure within a barn. Straw on floor with fecal debris. The barn smelled strongly of ammonia. No access to food or water.</p>	<p>This puppy is of ideal body condition at a score of 5/9 on the Purina scale. Deciduous teeth are present and feces are caked between paw pads.</p>	<p>PCV/TS- 38%/6.9, 4DX- too young, Fecal pending.</p>	<p>Vaccinated (Rabies, DAPP, Bordetella), dewormed, started on flea/tick preventative and heartworm preventative.</p>
<p>2038-1A-025</p>		<p>White, male, Samoyed-type puppy</p>	<p>Co-housed in wood and chain-link enclosure within a barn. Straw on floor with fecal debris. The barn smelled strongly of ammonia. No access to food or water.</p>	<p>This puppy is thin at a body condition score of 3/9 on the Purina scale, otherwise appears healthy.</p>	<p>PCV/TS- 33%/7.1, 4DX- too young, Fecal pending.</p>	<p>Vaccinated (Rabies, DAPP, Bordetella), dewormed, started on flea/tick preventative and heartworm preventative. Recheck weight in 1 month with proper diet and nutrition.</p>
<p>2038-1A-026</p>		<p>White, female, Samoyed-type puppy</p>	<p>Co-housed in wood and chain-link enclosure within a barn. Straw on floor with fecal debris. The barn smelled strongly of ammonia. No access to food or water.</p>	<p>This puppy is lean at a body condition score of 4/9 on the Purina scale. Coat has dirt and fecal matter, otherwise apparently healthy puppy.</p>	<p>PCV/TS- 39%/6.7, 4DX- too young, Fecal pending.</p>	<p>Vaccinated (Rabies, DAPP, Bordetella), dewormed, started on flea/tick preventative and heartworm preventative.</p>



<p>2038-1A-027</p>		<p>White, female, Samoyed-type puppy</p>	<p>Co-housed in wood and chain-link enclosure within a barn. Straw on floor with fecal debris. The barn smelled strongly of ammonia. No access to food or water.</p>	<p>This puppy is lean at a body condition score of 4/9 on the Purina scale. Dirt/debris on matatarsus and metacarpal regions.</p>	<p>PCV/TS- 39%/6.9, 4DX- too young, Fecal pending.</p>	<p>Vaccinated (Rabies, DAPP, Bordetella), dewormed, started on flea/tick preventative and heartworm preventative. Recommend clipping and cleaning areas of debris.</p>
<p>2038-1A-028</p>		<p>White, female, Samoyed-type puppy</p>	<p>Co-housed in wood and chain-link enclosure within a barn. Straw on floor with fecal debris. The barn smelled strongly of ammonia. No access to food or water.</p>	<p>This puppy is lean at a body condition score of 4/9 on the Purina scale. Mild pododermatitis on front feet. Debris and feces are present between digits. Nails are overgrown. Pyrexia (103.0°) is present.</p>	<p>PCV/TS- 33%/7.1, 4DX- too young, Fecal pending.</p>	<p>Vaccinated (Rabies, DAPP, Bordetella), dewormed, started on flea/tick preventative and heartworm preventative. Recommend clipping and cleaning front feet, recheck temperature tomorrow am, nail trim.</p>



<p>2038-1A-029</p>		<p>White, female, Samoyed-type puppy</p>	<p>Co-housed in wood and chain-link enclosure within a barn. Straw on floor with fecal debris. The barn smelled strongly of ammonia. No access to food or water.</p>	<p>This puppy is lean at a body condition score of 4/9 on the Purina scale. Apparently healthy puppy with mild dirt and debris in coat.</p>	<p>PCV/TS- 37%/6.7, 4DX- too young, Fecal pending.</p>	<p>Vaccinated (Rabies, DAPP, Bordetella), dewormed, started on flea/tick preventative and heartworm preventative.</p>
<p>2038-1A-030</p>		<p>White, young adult, male, Samoyed-type dog</p>	<p>Co-housed in wood and chain-link enclosure within a barn. Straw on floor with fecal debris. The barn smelled strongly of ammonia. No access to food or water.</p>	<p>This dog is lean at a body condition score of 4/9 on the Purina scale. Unilaterally cryptorchid with mild dental disease, ocular discharge, dirty coat, and mildly overgrown nails are present.</p>	<p>PCV/TS-40 %/8.1, 4DX- Negative, Fecal pending.</p>	<p>Vaccinated (Rabies, DAPP, Bordetella), dewormed, started on flea/tick preventative and heartworm preventative. Recommend nail trim, bath, reassess dental status in 6 months, and clean face and recheck eye discharge in 3 days.</p>



<p>2038-1A-031</p>		<p>White, male, Samoyed-type puppy</p>	<p>Co-housed in wood and chain-link enclosure within a barn. Straw on floor with fecal debris. The barn smelled strongly of ammonia. No access to food or water.</p>	<p>This puppy is of ideal body condition at a score of 5/9 on the Purina scale. Mild dental disease, dirty coat, overgrown nails, and irregular testicles are present.</p>	<p>PCV/TS- 41%/6.8, 4DX- Negative, Fecal pending.</p>	<p>Vaccinated (Rabies, DAPP, Bordetella), dewormed, started on flea/tick preventative and heartworm preventative. Recommend neuter, nail trim, bath, and reassess dental status in 6 months.</p>
<p>2038-1A-032</p>		<p>White, female, Samoyed-type puppy</p>	<p>Co-housed in wood and chain-link enclosure within a barn. Straw on floor with fecal debris. The barn smelled strongly of ammonia. No access to food or water.</p>	<p>This puppy is lean at a body condition score of 4/9 on the Purina scale. Apparently healthy with a dirty coat.</p>	<p>PCV/TS- 42%/6.9, 4DX- Negative, Witness pregnancy test- Negative, Fecal pending.</p>	<p>Vaccinated (Rabies, DAPP, Bordetella), dewormed, started on flea/tick preventative and heartworm preventative.</p>



<p>2038-1A-033</p>		<p>White, male, Samoyed-type puppy</p>	<p>Co-housed in wood and chain-link enclosure within a barn. Straw on floor with fecal debris. The barn smelled strongly of ammonia. No access to food or water.</p>	<p>This puppy is lean at a body condition score of 4/9 on the Purina scale. Puppy sedated for exam. Mild ocular discharge is present, otherwise apparently healthy puppy.</p>	<p>PCV/TS- 42%/7.4, 4DX- Negative, CBC/Chem and Fecal pending.</p>	<p>Vaccinated (Rabies, DAPP, Bordetella), dewormed, started on flea/tick preventative and heartworm preventative. Cleaned eyes, recommend recheck in 3 days.</p>
<p>2038-1A-034</p>		<p>White, female, Samoyed-type puppy</p>	<p>Co-housed in wood and chain-link enclosure within a barn. Straw on floor with fecal debris. The barn smelled strongly of ammonia. No access to food or water.</p>	<p>This puppy is lean at a body condition score of 4/9 on the Purina scale. A pink, nylon collar is tight on neck and was removed during exam. Ocular discharge, dirty coat and overgrown nails are present.</p>	<p>PCV/TS- 42%/7.3, 4DX- Negative, Witness pregnancy test- Negative, Fecal pending.</p>	<p>Vaccinated (Rabies, DAPP, Bordetella), dewormed, started on flea/tick preventative and heartworm preventative. Recommend cleaning face and recheck ocular discharge in 3 days. Nail trim.</p>



<p>2038-1A-035</p>		<p>White, female, Samoyed-type puppy</p>	<p>Co-housed in wood and chain-link enclosure within a barn. Straw on floor with fecal debris. The barn smelled strongly of ammonia. No access to food or water.</p>	<p>This puppy is lean at a body condition score of 4/9 on the Purina scale. Coat is dirty with matted debris near rear interdigital spaces.</p>	<p>PCV/TS- 43%/6.8, 4DX- Negative, Witness pregnancy test- Negative, Fecal pending.</p>	<p>Vaccinated (Rabies, DAPP, Bordetella), dewormed, started on flea/tick preventative and heartworm preventative. Recommend bath, groom rear feet.</p>
<p>2038-1A-036</p>		<p>White, male, Samoyed-type puppy</p>	<p>Co-housed in wood and chain-link enclosure within a barn. Straw on floor with fecal debris. The barn smelled strongly of ammonia. No access to food or water.</p>	<p>This puppy is of ideal body condition at a score of 5/9 on the Purina scale. Mild dental disease and dirty, matted coat are present.</p>	<p>PCV/TS- 41%/6.8, 4DX- Negative, Fecal pending.</p>	<p>Vaccinated (Rabies, DAPP, Bordetella), dewormed, started on flea/tick preventative and heartworm preventative. Recommend bath, reassess dental stage in 6 months.</p>
<p>2038-1A-037</p>		<p>White, young adult, female, Samoyed-type dog</p>	<p>Co-housed in wood and chain-link enclosure within a barn. Straw on floor with fecal debris. The barn smelled strongly of ammonia. No access to food or water.</p>	<p>This dog is lean at a body condition score of 4/9 on the Purina scale. Mild dental disease, mild matting and overgrown nails are present.</p>	<p>PCV/TS- 42%/6.4, 4DX-Negative, Witness pregnancy test- Negative, Fecal pending.</p>	<p>Vaccinated (Rabies, DAPP, Bordetella), dewormed, started on flea/tick preventative and heartworm preventative. Recommend nail trim and groom.</p>



<p>2038-1A-038</p>		<p>White, adult male, Samoyed-type dog</p>	<p>Co-housed in wood and chain-link enclosure within a barn. Straw on floor with fecal debris. The barn smelled strongly of ammonia. No access to food or water.</p>	<p>This dog is lean at a body condition score of 4/9 on the Purina scale. Blue nylon collar tight around neck removed during exam. Collar circumference 13.5", neck circumference 15.75". Mild dental disease, matted, dirty coat, and overgrown nails are present.</p>	<p>PCV/TS- 42%/7.4, 4DX- Negative, Fecal pending.</p>	<p>Vaccinated (Rabies, DAPP, Bordetella), dewormed, started on flea/tick preventative and heartworm preventative. Recommend nail trim, nutritional management, and reassess dental status in 6 months.</p>
<p>2038-1A-039</p>		<p>White, female, Samoyed-type puppy</p>	<p>Co-housed in wood and chain-link enclosure within a barn. Straw on floor with fecal debris. The barn smelled strongly of ammonia. No access to food or water.</p>	<p>This puppy is lean at a body condition score of 4/9 on the Purina scale. Sedated for exam. Apparently healthy puppy with dirty hair coat.</p>	<p>PCV/TS- 43%/7.2, 4DX- Negative, Witness pregnancy test- Negative, Fecal pending.</p>	<p>Vaccinated (Rabies, DAPP, Bordetella), dewormed, started on flea/tick preventative and heartworm preventative.</p>


<p>2038-1A-040</p>		<p>White, young adult, female, Samoyed-type dog</p>	<p>Co-housed in wood and chain-link enclosure within a barn. Straw on floor with fecal debris. The barn smelled strongly of ammonia. No access to food or water.</p>	<p>This dog is thin at a body condition score of 3/9 on the Purina scale. Sedated for exam. Dirty hair coat and overgrown nails, examination limited due to sedation.</p>	<p>PCV/TS- 40%/6.1, 4DX- Negative, Witness pregnancy test- , CBC/Chem and Fecal pending.</p>	<p>Vaccinated (Rabies, DAPP, Bordetella), dewormed, started on flea/tick preventative and heartworm preventative. Bath and nail trim. Nutritional management and monthly weight monitoring.</p>
<p>2038-1A-041</p>		<p>White, male, Samoyed-type puppy</p>	<p>Co-housed in wood and chain-link enclosure within a barn. Straw on floor with fecal debris. The barn smelled strongly of ammonia. No access to food or water.</p>	<p>This puppy is thin at a body condition score of 3/9 on the Purina scale. Dirty coat and overgrown nails are present.</p>	<p>PCV/TS- 43%/6.4, 4DX- Negative, CBC/Chem and Fecal pending.</p>	<p>Vaccinated (Rabies, DAPP, Bordetella), dewormed, started on flea/tick preventative and heartworm preventative. Nutritional management and recheck weight.</p>


<p>2038-1A-042</p>		<p>White, young adult male, Samoyed-type dog</p>	<p>Co-housed in wood and chain-link enclosure within a barn. Straw on floor with fecal debris. The barn smelled strongly of ammonia. No access to food or water.</p>	<p>This dog is lean at a body condition score of 4/9 on the Purina scale. Dirty coat, tight matting, and overgrown nails are present.</p>	<p>PCV/TS- 37%/8.0, 4DX- Negative, Fecal pending.</p>	<p>Vaccinated (Rabies, DAPP, Bordetella), dewormed, started on flea/tick preventative and heartworm preventative. Recommend nail trim and expedited grooming.</p>
<p>2038-1A-043</p>		<p>White, male, Samoyed-type puppy</p>	<p>Co-housed in wood and chain-link enclosure within a barn. Straw on floor with fecal debris. The barn smelled strongly of ammonia. No access to food or water.</p>	<p>This puppy is thin at a body condition score of 3/9 on the Purina scale. Overgrown nails and debris present near anus.</p>	<p>PCV/TS-49%/7.3. 4DX- negative. Fecal pending.</p>	<p>Vaccinated (Rabies, DAPP, Bordetella), dewormed, started on flea/tick preventative and heartworm preventative. Recommend nail trim and clip debris, clean coat. Nutritional management and recheck weight.</p>


<p>2038-1A-044</p>		<p>White, young adult female, Samoyed-type dog</p>	<p>Co-housed in wood and chain-link enclosure within a barn. Straw on floor with fecal debris. The barn smelled strongly of ammonia. No access to water. Food dishes had dry kibble present.</p>	<p>This dog is lean at a body condition score of 4/9 on the Purina scale. Pink, loosely fitting collar present. Scleral hemorrhage of the right eye. Moderately matted hair coat and overgrown nails.</p>	<p>PCV/TS- 48%/7.8, 4DX- negative, CBC/Chem Witness Pregnancy and Fecal pending.</p>	<p>Vaccinated (Rabies, DAPP, Bordetella), dewormed, started on flea/tick preventative and heartworm preventative. Groom and trim nails. Recheck scleral hemorrhage in one week.</p>
<p>2038-1A-045</p>		<p>White, adult male, Samoyed-type dog</p>	<p>Co-housed in wood and chain-link enclosure within a barn. Straw on floor with fecal debris. The barn smelled strongly of ammonia. No access to water. Food dishes had dry kibble present.</p>	<p>This dog is thin at a body condition score of 3/9 on the Purina scale. Sedated for exam. Pale pink mucus membranes/slightly cyanotic (reversed with 0m4 ml antisedan). Mild dental disease, elevated temperature (104.1°) likely due to stress, moderately matted coat.</p>	<p>PCV/TS- 42%/6.9, 4DX- negative, CBC/Chem pending. Fecal negative</p>	<p>Vaccinated (Rabies, DAPP, Bordetella), dewormed, started on flea/tick preventative and heartworm preventative. Increase nutritional plane, recheck weight in 2 weeks.</p>


<p>2038-1A-046</p>		<p>White, young adult female, Samoyed-type dog</p>	<p>Co-housed in wood and chain-link enclosure within a barn. Straw on floor with fecal debris. The barn smelled strongly of ammonia. No access to water. Food dishes had dry kibble present.</p>	<p>This dog is of ideal body condition at a score of 5/9 on the Purina scale. Mild dental disease, mild matting, and overgrown nails are present.</p>	<p>PCV/TS- 49%/7.2, 4DX- negative, Witness pregnancy - negative. CBC/Chem pending. Fecal negative.</p>	<p>Vaccinated (Rabies, DAPP, Bordetella), dewormed, started on flea/tick preventative and heartworm preventative. Bath, brush, and trim nails. Recommend behavior evaluation +/- anxiolytics.</p>
<p>2038-1A-047</p>		<p>White, young adult male, Samoyed-type dog</p>	<p>Co-housed in wood and chain-link enclosure within a barn. Straw on floor with fecal debris. The barn smelled strongly of ammonia. No access to water. Food dishes had dry kibble present.</p>	<p>This dog is lean at a body condition score of 4/9 on the Purina scale. Mild dental disease, moderate matting and overgrown nails present.</p>	<p>PCV/TS- 43%/8.2, 4DX- negative, CBC/Chem and Fecal pending.</p>	<p>Vaccinated (Rabies, DAPP, Bordetella), dewormed, started on flea/tick preventative and heartworm preventative. Recommend grooming/nail trim and behavior evaluation for possible anxiolytics.</p>

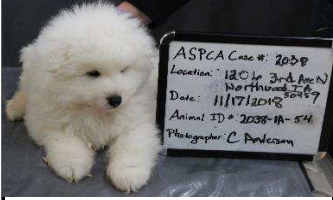

<p>2038-1A-048</p>		<p>White, young adult female, Samoyed-type dog</p>	<p>Co-housed in wood and chain-link enclosure within a barn. Straw on floor with fecal debris. The barn smelled strongly of ammonia. No access to water. Food dishes had dry kibble present.</p>	<p>This dog is lean at a body condition score of 4/9 on the Purina scale. Mild dental disease, retained dental fracture, dirty hair coat with minimal matting, and overgrown nails.</p>	<p>PCV/TS- 42%/6.8, 4DX- negative, Witness pregnancy, CBC/Chem and Fecal pending.</p>	<p>Vaccinated (Rabies, DAPP, Bordetella), dewormed, started on flea/tick preventative and heartworm preventative. Recommend dental assessment, removal of retained tooth, nail trim, and groom.</p>
<p>2038-1A-049</p>		<p>White, adult male, Samoyed-type dog</p>	<p>Singly-housed. Free roaming in barn and attached yard with no access to food or water.</p>	<p>This dog is thin at a body condition score of 3/9 on the Purina scale. Moderate dental disease, dirty matted coat with collar caught in fur, flea dirt, and otic discharge present. Alopecia on pinnae, bloody urine observed in kennel, and nuclear sclerosis consistent with age.</p>	<p>PCV/TS- 36%/7.6, 4DX- negative, Ear cytology-pending, UA-pending, CBC/Chem - pending. Fecal negative.</p>	<p>Vaccinated (Rabies, DAPP, Bordetella), dewormed, started on flea/tick preventative and heartworm preventative. Recommend groom, ear treatment based on results of cytology, urinary treatment based on results of UA, and dental assessment/cleaning. Nutritional management and recheck weight.</p>

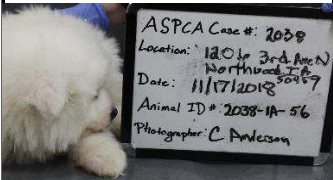
<p>2038-1A-050</p>		<p>White, adult female, Samoyed-type dog</p>	<p>Co-housed with puppies in a stand-alone elevated wooden barn. Stray bedding has a build-up of urine and feces. Items stored within barn include fans, bandsaw, and lawn tools. No access to food. Frozen water was present.</p>	<p>This dog is very thin at a body condition score of 2/9 on the Purina scale. Mild otic wax and debris, mild to moderate dental disease, matted and dirty coat.</p>	<p>PCV/TS- 41%/7.3, 4DX- negative, Witness pregnancy test-negative, CBC/Chem pending. Fecal roundworms.</p>	<p>Vaccinated (Rabies, DAPP, Bordetella), dewormed, started on flea/tick preventative and heartworm preventative. Recheck dental status in 6 months. Recheck weight after 2 weeks on nutritional diet. Trim nails, clip and clean coat.</p>
--------------------	---	--	--	--	---	---



<p>2038-1A-051</p>		<p>White, male, Samoyed-type puppy</p>	<p>Co-housed with bitch and littermates in a stand-alone elevated wooden barn. Stray bedding has a build-up of urine and feces. Items stored within barn include but not limited to fans, bandsaw, and lawn tools. No access to food. Frozen water was present.</p>	<p>This puppy is of ideal body condition at a score of 5/9 on the Purina scale. Apparently healthy puppy with overgrown nails.</p>	<p>PCV/TS- 34%/6.0, Fecal pending.</p>	<p>Vaccinated (DAPP, Bordetella), dewormed, started on flea/tick preventative and heartworm preventative. Trim nails.</p>
--------------------	---	--	---	--	--	---


<p>2038-1A-052</p>		<p>White, male, Samoyed-type puppy</p>	<p>Co-housed with bitch and littermates in a stand-alone elevated wooden barn. Stray bedding has a build-up of urine and feces. Items stored within barn include but not limited to fans, bandsaw, and lawn tools. No access to food. Frozen water was present.</p>	<p>This puppy is of ideal body condition at a score of 5/9 on the Purina scale. Possible congenital cataract and overgrown nails.</p>	<p>PCV/TS- 34%/6.3, Fecal pending.</p>	<p>Vaccinated (DAPP, Bordetella), dewormed, started on flea/tick preventative and heartworm preventative. Reassess eye, possible ophthalmic consultation. Trim nails.</p>
--------------------	---	--	---	---	--	---

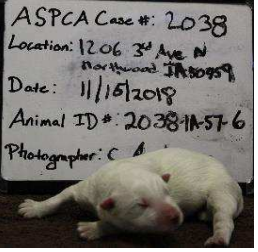
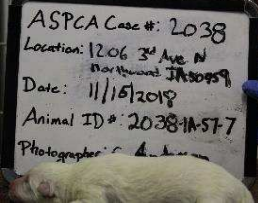
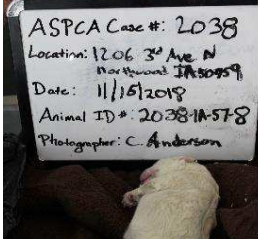
<p>2038-1A-53</p>		<p>White, adult female, Samoyed-type dog</p>	<p>Co-housed with bitch and littermates in a stand-alone elevated wooden barn. Stray bedding has a build-up of urine and feces. Items stored within barn include but not limited to fans, bandsaw, and lawn tools. No access to food. Frozen water was present.</p>	<p>This dog is thin at a body condition score of 3/9 on the Purina scale. Circumference of pink collar is 37 cm, neck circumference is 32.5 cm. Nails are overgrown. Dirt and debris are present around ears, and matting is present through out coat. Mild dental disease is present.</p>	<p>PCV/TS- 41%/8.2, Witness Pregnancy test- Positive, Fecal pending.</p>	<p>Vaccinated (Rabies, DAPP, Bordetella), dewormed, started on flea/tick preventative and heartworm preventative. Recheck weight in 1 month with proper diet and nutrition, trim nails, clean ears, clip and clean fur. Recheck dental status in 1 year.</p>
-------------------	---	--	---	--	--	--



<p>2038-1A-54</p>		<p>White, male, Samoyed-type puppy</p>	<p>Co-housed with bitch and littermates in a stand-alone elevated wooden barn. Stray bedding has a build-up of urine and feces. Items stored within barn include but not limited to fans, bandsaw, and lawn tools. No access to food. Frozen water was present.</p>	<p>This puppy is lean at a body condition score of 4/9 on the Purina scale. Apparently healthy.</p>	<p>PCV/TS- 30%/6.3, Fecal pending.</p>	<p>Vaccinated (Rabies, DAPP, Bordetella), dewormed, started on flea/tick preventative and heartworm preventative.</p>
<p>2038-1A-55</p>		<p>White, female, Samoyed-type puppy</p>	<p>Co-housed in a wooden horse stall in a barn with straw bedding. There is a tan couch within the stall. No access to food or water.</p>	<p>This puppy is lean at a body condition score of 4/9 on the Purina scale. Apparently healthy.</p>	<p>PCV/TS- 34%/5.9, Fecal pending.</p>	<p>Vaccinated (Rabies, DAPP, Bordetella), dewormed, started on flea/tick preventative and heartworm preventative.</p>



<p>2038-1A-56</p>		<p>White, male, Samoyed-type puppy</p>	<p>Co-housed with bitch and littermates in a stand-alone elevated wooden barn. Stray bedding has a build-up of urine and feces. Items stored within barn include but not limited to fans, bandsaw, and lawn tools. No access to food. Frozen water was present.</p>	<p>This puppy is lean at a body condition score of 4/9 on the Purina scale. Cryptorchid male otherwise apparently healthy.</p>	<p>PCV/TS- 31%/5.9, Fecal pending.</p>	<p>Vaccinated (Rabies, DAPP, Bordetella), dewormed, started on flea/tick preventative and heartworm preventative. Recheck testicles in 1 month.</p>
-------------------	---	--	---	--	--	---



<p>2038-1A-57</p>		<p>White, adult female, Samoyed-type dog</p>	<p>Singly housed in a wooden barn stall. Straw bedding has feces present. Frozen water is present, no food is available. Odor of ammonia present.</p>	<p>This dog is very thin at a body condition score of 2/9 on the Purina scale. Bilateral green ocular discharge. Pale pink mucus membranes, possibly anemic. Mild dental disease with hypersalivation. Moderate generalized muscle wasting. Late term pregnancy. Dull, dirty coat with generalized mild to moderate matting. Pink collar loosely fitted.</p>	<p>PCV/TS- 31%/7.2, 4DX-negative, Fecal, CBC/Chem pending.</p>	<p>Vaccinated (Rabies, DAPP, Bordetella), dewormed, started on flea/tick preventative and heartworm preventative. Recommend radiographs to confirm progression of pregnancy and/or OHE. Monitor for signs of whelping. Monitor appetite and stool, recommend wet food to increase weight. Groom.</p>
<p>2038-1A-57.1</p>	 <p>Location: 1206 3rd Ave N Northwood, IA 50959 Date: 11/15/2018 Animal ID #: 2038-1A-57-1 by: C. Anderson</p>	<p>White, female, Samoyed-type puppy</p>	<p>Born while in ASPCA care.</p>	<p>This puppy is of ideal body condition at a score of 5/9 on the Purina scale. Apparently healthy.</p>	<p>No diagnostics performed</p>	<p>Provide warm, quiet environment for growth. Proceed with vaccination and deworming when age appropriate.</p>


2038-1A-57.2		White, male, Samoyed-type puppy	Born while in ASPCA care.	This puppy is of ideal body condition at a score of 5/9 on the Purina scale. Apparently healthy.	No diagnostics performed	Provide warm, quiet environment for growth. Proceed with vaccination and deworming when age appropriate.
2038-1A-57.3		White, male, Samoyed-type puppy	Born while in ASPCA care.	This puppy is of ideal body condition at a score of 5/9 on the Purina scale. Apparently healthy.	No diagnostics performed	Provide warm, quiet environment for growth. Proceed with vaccination and deworming when age appropriate.
2038-1A-57.4		White, female, Samoyed-type puppy	Born while in ASPCA care.	This puppy is of ideal body condition at a score of 5/9 on the Purina scale. Apparently healthy.	No diagnostics performed	Provide warm, quiet environment for growth. Proceed with vaccination and deworming when age appropriate.
2038-1A-57.5		White, female, Samoyed-type puppy	Born while in ASPCA care.	This puppy is of ideal body condition at a score of 5/9 on the Purina scale. Apparently healthy.	No diagnostics performed	Provide warm, quiet environment for growth. Proceed with vaccination and deworming when age appropriate.


2038-1A-57.6		White, female, Samoyed-type puppy	Born while in ASPCA care.	This puppy is of ideal body condition at a score of 5/9 on the Purina scale. Apparently healthy.	No diagnostics performed	Provide warm, quiet environment for growth. Proceed with vaccination and deworming when age appropriate.
2038-1A-57.7		White, male, Samoyed-type puppy	Born while in ASPCA care.	This puppy is of ideal body condition at a score of 5/9 on the Purina scale. Apparently healthy.	No diagnostics performed	Provide warm, quiet environment for growth. Proceed with vaccination and deworming when age appropriate.
2038-1A-57.8		White, female, Samoyed-type puppy	Born while in ASPCA care.	This puppy is of ideal body condition at a score of 5/9 on the Purina scale. Apparently healthy.	Necropsy pending,	Provide warm, quiet environment for growth. Proceed with vaccination and deworming when age appropriate.


<p>2038-1A-58</p>		<p>White, female, Samoyed-type puppy</p>	<p>Co-housed with puppies in a wooden barn stall. Straw bedding has feces present. Frozen water is present, no food is available. Odor of ammonia present.</p>	<p>This dog is lean at a body condition score of 4/9 on the Purina scale. Pyrexia (104.1), mild to moderate dental disease, and matting are present. Nails are overgrown.</p>	<p>PCV/TS- 41%/8.0, 4DX-negative, Witness pregnancy test-negative, Fecal, CBC/Chem pending</p>	<p>Vaccinated (Rabies, DAPP, Bordetella), dewormed, started on flea/tick preventative and heartworm preventative. Recommend recheck temperature in 2 hours, recheck weight in 2 weeks, and recheck dental in 1 year.</p>
<p>2038-1A-59</p>		<p>Puppy, male, white Samoyed-type puppy</p>	<p>Co-housed with littermates and bitch in a wooden barn stall. Straw bedding has feces present. Frozen water is present, no food is available. Odor of ammonia present.</p>	<p>This puppy is of ideal body condition at a score of 5/9 on the Purina Scale. Pale pink mucous membranes. Mildly watery eyes, not clinical. Yellow diarrhea with palpable thickened intestines. Abdomen is slightly distended. Overgrown nails.</p>	<p>PCV/TS- 29%/ 6.2, Fecal pending.</p>	<p>Vaccinated (DAPP, Bordetella), dewormed, started on flea/tick preventative and heartworm preventative. Provide nail trim. Pending fecal results, treat suspected intestinal parasites.</p>


<p>2038-1A-60</p>		<p>Puppy, male, white Samoyed-type puppy</p>	<p>Co-housed with littermates and bitch in a wooden barn stall. Straw bedding has feces present. Frozen water is present, no food is available. Odor of ammonia present.</p>	<p>This puppy is lean at a body condition score of 4/9 on the Purina Scale. Mildly watery eyes, not clinical. Slightly distended abdomen. Overgrown nails.</p>	<p>PCV/TS- 30%/ 5.3, Fecal pending.</p>	<p>Vaccinated (DAPP, Bordetella), dewormed, started on flea/tick preventative and heartworm preventative. Pending fecal results, treat suspected intestinal parasites. Provide nail trim.</p>
<p>2038-1A-61</p>		<p>Puppy, female, white Samoyed-type puppy</p>	<p>Co-housed with littermates and bitch in a wooden barn stall. Straw bedding has feces present. Frozen water is present, no food is available. Odor of ammonia present.</p>	<p>This puppy is of ideal body condition at a score of 5/9 on the Purina Scale. Moderate to severe microphthalmia with no menace. Mildly distended abdomen. Overgrown nails.</p>	<p>PCV/TS- 30%/7.1, Fecal pending.</p>	<p>Vaccinated (DAPP, Bordetella), dewormed, started on flea/tick preventative and heartworm preventative. Trim nails. Provide ophthalmic consultation.</p>


<p>2038-1A-62</p>		<p>Puppy, female, white Samoyed-type puppy</p>	<p>Co-housed with littermates and bitch in a wooden barn stall. Straw bedding has feces present. Frozen water is present, no food is available. Odor of ammonia present.</p>	<p>This puppy is over conditioned at a body condition score of 6/9 on the Purina Scale. She has slightly distended abdomen. Overgrown nails.</p>	<p>PCV/TS- 31%/6.1, Fecal pending.</p>	<p>Vaccinated (DAPP, Bordetella), dewormed, started on flea/tick preventative and heartworm preventative. Trim nails.</p>
<p>2038-1A-63</p>		<p>Puppy, female, white Samoyed-type puppy</p>	<p>Co-housed with littermates and bitch in a wooden barn stall. Straw bedding has feces present. Frozen water is present, no food is available. Odor of ammonia present.</p>	<p>This puppy is over conditioned at a body condition score of 6/9 on the Purina Scale. There is mild tear staining of both eyes. Abdomen is mildly distended. Overgrown nails.</p>	<p>PCV/TS- 30%/6.1, 4DX- , Witness pregnancy test- , CBC/Chem and Fecal pending.</p>	<p>Vaccinated (DAPP, Bordetella), dewormed, started on flea/tick preventative and heartworm preventative.</p>


<p>2038-1A-64</p>		<p>Young-adult, female, white Samoyed-type dog</p>	<p>Co-housed with indoor/outdoor access. Outdoor perimeter lined with metal fence. A wooden structure composed of four wooden walls with an entry way, dirt floor, and metal roof. Multiple holes dug in the outdoor area, a frozen puddle was in the outdoor area. No water or food was present.</p>	<p>This dog is lean at a body condition score of 4/9 on the Purina Scale. Grade 1/4 dental disease with mild tartar. Generalized fur matting with large mat over the right shoulder. Matting of fur with fecal material of rump region. Overgrown nails.</p>	<p>PCV/TS- 49%/7.6, 4DX- negative, Witness pregnancy test-negative, Fecal pending.</p>	<p>Vaccinated (Rabies, DAPP, Bordetella), dewormed, started on flea/tick preventative and heartworm preventative. Provide grooming and nail trim. Reassess dental status in 6 months.</p>
-------------------	---	--	---	--	--	---


<p>2038-1A-65</p>		<p>Adult, male, white Samoyed-type dog</p>	<p>Co-housed with indoor/outdoor access. Outdoor perimeter lined with metal fence. A wooden structure composed of four wooden walls with an entry way, dirt floor, and metal roof. Multiple holes dug in the outdoor area, a frozen puddle was in the outdoor area. No water or food was present.</p>	<p>This dog is lean at a body condition score of 4/9 on the Purina Scale. Grade 1/4 dental disease with mild tartar and gingivitis. Generalized matting of fur.</p>	<p>PCV/TS- 39%/7.9, 4DX- negative, Fecal pending.</p>	<p>Vaccinated (Rabies, DAPP, Bordetella), dewormed, started on flea/tick preventative and heartworm preventative. Provide grooming. Reassess dental status in 1 year.</p>
-------------------	---	--	---	---	---	---


<p>2038-1A-66</p>		<p>Young-adult, male, white Samoyed-type dog</p>	<p>Co-housed with indoor/outdoor access. Outdoor perimeter lined with metal fence. A wooden structure composed of four wooden walls with an entry way, dirt floor, and metal roof. Multiple holes dug in the outdoor area, a frozen puddle was in the outdoor area. No water or food was present.</p>	<p>This dog is thin at a body condition score of 3/9 on the Purina Scale. Both eyes have suspected early cataract formation. The fur coat has generalized matting, feces are dried into some mats. Overgrown nails.</p>	<p>PCV/TS- 41%/7.3, 4DX- negative, CBC/Chem and Fecal pending.</p>	<p>Vaccinated (Rabies, DAPP, Bordetella), dewormed, started on flea/tick preventative and heartworm preventative. Provide grooming and nail trim. Reassess eyes in 6 months. Provide increase in nutritional plane for weight gain.</p>
-------------------	---	--	---	---	--	---


<p>2038-1A-67</p>		<p>Young-adult, male, white Samoyed-type dog</p>	<p>Co-housed with indoor/outdoor access. Outdoor perimeter lined with metal fence. A wooden structure composed of four wooden walls with an entry way, dirt floor, and metal roof. Multiple holes dug in the outdoor area, a frozen puddle was in the outdoor area. No water or food was present.</p>	<p>This dog is thin at a body condition score of 3/9 on the Purina Scale. Both eyes have immature cataracts. Dirty fur coat with overgrown nails.</p>	<p>PCV/TS-41%/ 7.1, 4DX- negative, CBC/Chem and Fecal pending.</p>	<p>Vaccinated (Rabies, DAPP, Bordetella), dewormed, started on flea/tick preventative and heartworm preventative. Recheck cataracts in 6 months. Increase nutritional plane for weight gain.</p>
-------------------	---	--	---	---	--	--


<p>2038-1A-68</p>		<p>Adult, male, white Samoyed-type dog</p>	<p>Co-housed with indoor/outdoor access. Outdoor perimeter lined with metal fence. A wooden structure composed of four wooden walls with an entry way, dirt floor, and metal roof. Multiple holes dug in the outdoor area. Scant frozen water was present. No food was available.</p>	<p>This dog is thin at a body condition score of 3/9 on the Purina Scale. Retinal blood vessels are attenuated. Grade 1/4 dental disease with wear on the back of tooth 104 and 204. Tartar is present. Severe fur matting throughout coat. Overgrown nails, nails embedded in paw pads.</p>	<p>PCV/TS- 43%/6.7, 4DX- negative, and Fecal pending.</p>	<p>Vaccinated (Rabies, DAPP, Bordetella), dewormed, started on flea/tick preventative and heartworm preventative. Recommend an ophthalmology consultation. Recheck dental status in 6 months. Provide grooming and nail trim. Nutritional management and recheck weight.</p>
-------------------	---	--	---	--	---	--



<p>2038-1A-69</p>		<p>Adult, female, white Samoyed-type dog</p>	<p>Co-housed with indoor/outdoor access. Outdoor perimeter lined with metal fence. A wooden structure composed of four wooden walls with an entry way, dirt floor, and metal roof. Multiple holes dug in the outdoor area. Scant frozen water was present. No food was available.</p>	<p>This dog is thin at a body condition score of 3/9 on the Purina Scale. Ear tip has absent fur. Grade 2/4 dental disease with gingivitis, enamel wear on the upper incisors and upper canines, possible draining tract on tooth 108. Fecal material present around anus. Dirty generalized fur coat. Scar on the right metatarsus measuring 0.5 cm x 1 cm. Overgrown nails.</p>	<p>PCV/TS-50 %/7.1, 4DX- negative, Witness pregnancy test - positive. CBC/Chem and Fecal pending.</p>	<p>Vaccinated (Rabies, DAPP, Bordetella), dewormed, started on flea/tick preventative and heartworm preventative. Groom and provide nail trim. Recommend dental consultation. Increase nutritional plane for weight gain.</p>
-------------------	---	--	---	---	---	---



<p>2038-1A-70</p>		<p>Adult, female, white Samoyed-type dog</p>	<p>Co-housed with indoor/outdoor access. Outdoor perimeter lined with metal fence. A wooden structure composed of four wooden walls with an entry way, dirt floor, and metal roof. Multiple holes dug in the outdoor area. Scant frozen water was present. No food was available.</p>	<p>This dog is lean at a body condition score of 4/9 on the Purina Scale. Grade 3/4 dental disease with moderate calculus accumulation and inflammation of the gums. Gum line around tooth 204 has yellow coloring due to suspected abscess. On cardiac auscultation, gallop rhythm. Mammary development consistent with previous litters; dirt on mammary chain. Moderate fur matting particularly around the base of the ears, hind quarters, and tail. Raised lesion measuring 1 cm x 2 cm on left forearm with serosanguineous-bloody discharge. Large healing wound with fur loss and scar tissue over right side of abdomen measuring 2.5 in x 3.5 in, the central aspect of the scar has an area of 1x0.25 inch region of granulation tissue. Overgrown nails.</p>	<p>PCV/TS-49 %/6.4, 4DX- negative, Witness pregnancy test-pending, Fecal pending slightly increased at 16.6 (4.0-15.5) platelets sl increased insignificant NEUT and MONO sl increased R/O stress leukogram, Chemistry unremarkable. Fine Needle aspirate of left forearm lesion - pyogranulomatous</p>	<p>Vaccinated (Rabies, DAPP, Bordetella), dewormed, started on flea/tick preventative and heartworm preventative. Recommend NSAIDs pending diagnostics for pain associated with abscess on left forearm. Monitor abdominal wound for closure, may need surgical correction. Recommend priority dental cleaning.</p>
-------------------	---	--	---	---	---	---



<p>2038-1A-71</p>		<p>Adult, female, white Samoyed-type dog</p>	<p>Co-housed with indoor/outdoor access. Outdoor perimeter lined with metal fence. A wooden structure composed of four wooden walls with an entry way, dirt floor, and metal roof. Multiple holes dug in the outdoor area. Scant frozen water was present. No food was available.</p>	<p>This dog is thin at a body condition score of 3/9 on the Purina Scale. Grade 2/4 dental disease with mild to moderate tartar and calculus. Matting of tail. Feces present around anus. Fur mats between digits 3 and 4 on the right front foot. Fur mats behind the ears. Overgrown nails.</p>	<p>PCV/TS- 34%/ 7.8, 4DX- negative, Witness pregnancy test - positive. CBC/Chem and Fecal pending.</p>	<p>Vaccinated (Rabies, DAPP, Bordetella), dewormed, started on flea/tick preventative and heartworm preventative. Reassess dental status in 6 months. Increase nutritional plane for weight gain. Provide grooming and nail trim.</p>
-------------------	---	--	---	---	--	---



<p>2038-1A-72</p>		<p>Adult, female, white Samoyed-type dog</p>	<p>Co-housed with indoor/outdoor access. Outdoor perimeter lined with metal fence. A wooden structure composed of four wooden walls with an entry way, dirt floor, and metal roof. Multiple holes dug in the outdoor area. Scant frozen water was present. No food was available.</p>	<p>This dog is of ideal body condition at a score of 5/9 on the Purina Scale. Grade 2/4 dental disease with moderate calculus and incisors worn with tertiary dentin present. Left ear has moderate amount of dried debris and mildly reddened. Mammary glands developed. Dirty, dry fur coat with minimal matting. Small amount of feces present around anus. Moderately overgrown nails.</p>	<p>PCV/TS- 49%/7.1, 4DX- negative, Witness pregnancy test - negative. CBC/Chem, ear cytology, and Fecal pending.</p>	<p>Vaccinated (Rabies, DAPP, Bordetella), dewormed, started on flea/tick preventative and heartworm preventative. Treatment plan based on results of ear cytology. Provide grooming and nail trim.</p>
-------------------	---	--	---	--	--	--



<p>2083-1A-73</p>		<p>Adult, male, white Samoyed-type dog</p>	<p>Co-housed with indoor/outdoor access. Outdoor perimeter lined with metal fence. A wooden structure composed of four wooden walls with an entry way, dirt floor, and metal roof. Multiple holes dug in the outdoor area. Scant frozen water was present. No food was available.</p>	<p>This dog is lean at a body condition score of 4/9 on the Purina Scale. Grade 2/4 dental disease with uncomplicated fracture of the upper left incisor and mild to moderate tartar. Matted fur behind both ears, around the neck, on the tail, and the back of both thighs. Large dangling fur mats with debris from the back of both front legs. Dirty hair coat and overgrown nails.</p>	<p>PCV/TS- 46%/7.7, 4DX- negative, and Fecal pending.</p>	<p>Vaccinated (Rabies, DAPP, Bordetella), dewormed, started on flea/tick preventative and heartworm preventative. Provide grooming and nail trim. Recommend dental consultation due to fracture.</p>
-------------------	---	--	---	--	---	--




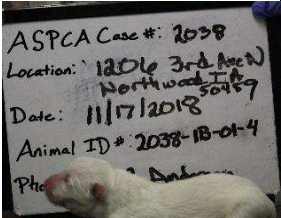
<p>2038-1A-74</p>		<p>Puppy, female, white Samoyed-type puppy</p>	<p>Co-housed within a barn stall with straw bedding.</p>	<p>This puppy is thin at a body condition score of 3/9 on the Purina Scale. Mild overbite.</p>	<p>PCV/TS- 37%/5.9, and Fecal pending.</p>	<p>Vaccinated (Rabies, DAPP, Bordetella), dewormed, started on flea/tick preventative and heartworm preventative. Increase nutritional plane for weight gain.</p>
<p>2038-1A-75</p>		<p>Puppy, male, white Samoyed-type puppy</p>	<p>Co-housed within a barn stall with straw bedding.</p>	<p>This puppy is thin at a body condition score of 3/9 on the Purina Scale. Intestinal parasite observed exiting from puppy's anus. Scant debris in fur coat.</p>	<p>PCV/TS-33%/5.8, and Fecal pending.</p>	<p>Vaccinated (Rabies, DAPP, Bordetella), dewormed, started on flea/tick preventative and heartworm preventative. Increase nutritional plane for weight gain.</p>




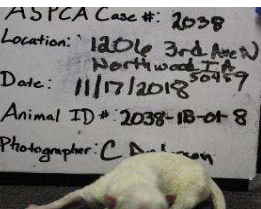
<p>2038-1A-76</p>		<p>Puppy, male, white Samoyed-type puppy</p>	<p>Co-housed within a barn stall with straw bedding.</p>	<p>This puppy is lean at a body condition score of 4/9 on the Purina Scale. Debris in fur coat. Severe pododermatitis of both rear feet. Moderate pododermatitis of both front feet.</p>	<p>PCV/TS- 35%/6.6, and Fecal pending.</p>	<p>Vaccinated (Rabies, DAPP, Bordetella), dewormed, started on flea/tick preventative and heartworm preventative. Clip and clean feet, recheck in 1 week, anticipate resolution with improvement of housing.</p>
<p>2038-1A-77</p>		<p>Puppy, female, white Samoyed-type puppy</p>	<p>Co-housed within a barn stall with straw bedding.</p>	<p>This puppy is lean at a body condition score of 4/9 on the Purina Scale. Mild overbite with malocclusion of 104. Tooth 404 is broken. Small amount of feces around the anus.</p>	<p>PCV/TS- 40%/6.6, and Fecal pending.</p>	<p>Vaccinated (Rabies, DAPP, Bordetella), dewormed, started on flea/tick preventative and heartworm preventative. Recheck dentition in 6 months. Clip and clean rump region.</p>



<p>2038-1A-78</p>		<p>Puppy, male, white Samoyed-type puppy</p>	<p>Co-housed within a barn stall with straw bedding.</p>	<p>This puppy is thin at a body condition score of 3/9 on the Purina Scale. Overgrown nails.</p>	<p>PCV/TS- 33%/6.1, 4DX-negative, Fecal pending.</p>	<p>Vaccinated (Rabies, DAPP, Bordetella), dewormed, started on flea/tick preventative and heartworm preventative. Nutritional management and recheck weight in 1 month. Provide a nail trim.</p>
<p>2038-1A-79</p>		<p>Puppy, female, white Samoyed-type puppy</p>	<p>Co-housed within a barn stall with straw bedding.</p>	<p>This puppy is of ideal body condition at a score of 5/9 on the Purina Scale.</p>	<p>PCV/TS- 40%/6.9, Fecal pending.</p>	<p>Vaccinated (Rabies, DAPP, Bordetella), dewormed, started on flea/tick preventative and heartworm preventative.</p>


<p>2038-1A-80</p>		<p>Puppy, female, white Samoyed-type puppy</p>	<p>Co-housed within a barn stall with straw bedding.</p>	<p>This puppy is lean at a body condition score of 4/9 on the Purina Scale. Mild clear discharge from both eyes, not clinical. Gas filled bowel loops palpable. Small fur mat behind ear.</p>	<p>PCV/TS- 36%/6.3, Fecal pending.</p>	<p>Vaccinated (Rabies, DAPP, Bordetella), dewormed, started on flea/tick preventative and heartworm preventative.</p>
<p>2038-1A-81</p>		<p>Puppy, female, white Samoyed-type puppy</p>	<p>Co-housed within a barn stall with straw bedding.</p>	<p>This puppy is of ideal body condition at a score of 5/9 on the Purina Scale. Slightly tacky mucous membranes. Mucoïd discharge from the right eye. Wearing a collar measuring 24.5 cm in diameter, neck measures 25 cm.</p>	<p>PCV/TS- 33%/6.7, Fecal pending.</p>	<p>Vaccinated (Rabies, DAPP, Bordetella), dewormed, started on flea/tick preventative and heartworm preventative. Re-evaluate patient's respiratory tract for signs of possible upper respiratory infection.</p>


<p>2038-1A-100</p>		<p>Puppy, female, white Samoyed-type puppy</p>	<p>Co-housed within a barn stall with straw bedding.</p>	<p>This puppy is overweight at a body condition score of 6/9 on the Purina Scale. Abdomen is distended. Nails are overgrown.</p>	<p>PCV/TS- 30%/6.1, Fecal pending.</p>	<p>Vaccinated (DAPP, Bordetella), dewormed, started on flea/tick preventative and heartworm preventative. Trim nails.</p>
<p>2038-1B-1</p>		<p>Adult, female, white Samoyed-type dog</p>	<p>Singly housed in a wooden structure with straw on the floor and a metal roof. The straw had a build-up of feces, a strong odor of ammonia was present. Two buckets of frozen water were available, one of the buckets had water underneath a layer of ice.</p>	<p>This dog is emaciated at a body condition score of 1/9 on the Purina Scale. Patient sedated for examination. Grade 1/4 dental disease with tartar on tooth 208 with suspected fracture. Abdomen significantly distended (pregnant) with mammary gland development. Debris and feces in fur. Overgrown nails.</p>	<p>PCV/TS- 28%/7.7, 4DX- negative, Witness pregnancy - positive. Fecal and CBC/Chemistry pending.</p>	<p>Vaccinated (Rabies, DAPP, Bordetella), dewormed, started on flea/tick preventative and heartworm preventative. Provide dental consultation for dental fracture within the next 2 months. Provide crucial nutritional management plan for weight gain.</p>


2038-1B-1.1		Neonate, male, white Samoyed-type puppy	Born while in ASPCA care.	This puppy is of ideal body condition at a score of 5/9 on the Purina Body Scale. Eyes and ears closed.	None	Provide warm, quiet environment for growth. Proceed with vaccination and deworming when age appropriate.
2038-1B-1.2		Neonate, female, white Samoyed-type puppy	Born while in ASPCA care.	This puppy is of ideal body condition at a score of 5/9 on the Purina Body Scale. Eyes and ears closed.	None	Provide warm, quiet environment for growth. Proceed with vaccination and deworming when age appropriate.
2038-1B-1.3		Neonate, female, white Samoyed-type puppy	Born while in ASPCA care.	This puppy is of ideal body condition at a score of 5/9 on the Purina Body Scale.	None	Provide warm, quiet environment for growth. Proceed with vaccination and deworming when age appropriate.
2038-1B-1.4		Neonate, male, white Samoyed-type puppy	Born while in ASPCA care.	This puppy is of ideal body condition at a score of 5/9 on the Purina Body Scale. Eyes and ears closed. Dried umbilicus present.	None	Provide warm, quiet environment for growth. Proceed with vaccination and deworming when age appropriate.


2038-1B-1.5		Neonate, male, white Samoyed-type puppy	Born while in ASPCA care.	This puppy is of ideal body condition at a score of 5/9 on the Purina Body Scale. Eyes and ears closed.	None	Provide warm, quiet environment for growth. Proceed with vaccination and deworming when age appropriate.
2038-1B-1.6		Neonate, female, white Samoyed-type puppy	Born while in ASPCA care.	This puppy is of ideal body condition at a score of 5/9 on the Purina Body Scale. Eyes and ears closed.	None	Provide warm, quiet environment for growth. Proceed with vaccination and deworming when age appropriate.
2038-1B-1.7		Neonate, male, white Samoyed-type puppy	Born while in ASPCA care.	This puppy is of ideal body condition at a score of 5/9 on the Purina Body Scale. Eyes and ears closed.	None	Provide warm, quiet environment for growth. Proceed with vaccination and deworming when age appropriate.
2038-1B-1.8		Neonate, male, white Samoyed-type puppy	Born while in ASPCA care.	This puppy is of ideal body condition at a score of 5/9 on the Purina Body Scale. Eyes and ears closed.	Necropsy pending,	Deceased


<p>2038-1B-1.9</p>		<p>Neonate, female, white Samoyed-type puppy</p>	<p>Born while in ASPCA care.</p>	<p>This puppy is of ideal body condition at a score of 5/9 on the Purina Body Scale. Eyes and ears closed.</p>	<p>Necropsy pending,</p>	<p>Deceased</p>
<p>2038-1B-2</p>		<p>Adult, male, white Samoyed-type dog</p>	<p>Co-housed in a wood building with indoor/outdoor access. Rubber flaps are at the indoor/outdoor entries. The yard facing the house has a concrete floor, metal roof and metal fencing. There is a partial doghouse constructed of wooden walls. The yard facing away from the house is frozen dirt flooring with metal fencing. Interior is a narrow space with dirt flooring and a strong odor of ammonia. Frozen water is available, no food is present.</p>	<p>This dog is very thin at a body condition score of 2/9 on the Purina Scale. Grade 2/4 dental disease with mild to moderate plaque on teeth and an area of mild redness over tooth 208. Left ear has moderate dark brown waxy debris with mild reddening. Moderate muscle wasting. Severe fur mats throughout the head, neck, trunk, and tail with mild debris present within the fur mats. Fecal matting in the tail and hind quarter fur. Fur coat is malodorous. Only 1-2 palpable coccygeal vertebrae. Moderately overgrown nails.</p>	<p>PCV/TS- 44%/7.8, 4DX- negative, Ear cytology - both ears have yeast. Fecal pending. CBC - WBC 19.9 (4.0-15.5) Eosinophils 3 fold increase; Chemistry - Globulin 3.9 g/dL (1.6-3.6)</p>	<p>Vaccinated (Rabies, DAPP, Bordetella), dewormed, started on flea/tick preventative and heartworm preventative. Increase nutritional plane for weight gain. Provide priority grooming and nail trim, re-examine skin after grooming. Provide treatment plan based on ear cytology results. Recommend a behavior assessment and implement anxiolytics. Monitor for straining to defecate. Reassess dental status in 6 months.</p>


<p>2038-1B-3</p>		<p>Adult, female, white Samoyed-type dog</p>	<p>Co-housed in a wood building with indoor/outdoor access. Rubber flaps are at the indoor/outdoor entries. The yard facing the house has a concrete floor, metal roof and metal fencing. There is a partial doghouse constructed of wooden walls. The yard facing away from the house is frozen dirt flooring with metal fencing. Interior is a narrow space with dirt flooring and a strong odor of ammonia. Frozen water is available, no food is present.</p>	<p>This dog is very thin at a body condition score of 2/9 on the Purina Scale. Grade 3/4 dental disease with heavy calculus. The gum line over tooth 208 has a 1 mm superficial laceration, does not appear painful. Developed mammary glands. Generalized muscle wasting. Diffusely dirty and discolored fur coat resulting in brown to gray coloring. Moderate to severe fur matting over the whole body. Overgrown nails.</p>	<p>PCV/TS- 32%/6.1, 4DX- negative, Witness pregnancy test-positive, Fecal pending. CBC - WBC 18.0 (4.0-15.5) Eosinophils 5,220 (29 0-1200) . Chemistry - CPK low at 48 IU/L (59-895)</p>	<p>Vaccinated (Rabies, DAPP, Bordetella), dewormed, started on flea/tick preventative and heartworm preventative. Increase nutritional plane for weight gain. Recommend priority grooming and nail trim. Reassess dental disease in 6 months.</p>
------------------	---	--	---	--	--	---

<p>2038-1B-4</p>		<p>Adult, female, white Samoyed-type dog</p>	<p>Co-housed in a wood building with indoor/outdoor access. Rubber flaps are at the indoor/outdoor entries. The yard facing the house has a concrete floor, metal roof and metal fencing. There is a partial doghouse constructed of wooden walls. The yard facing away from the house is frozen dirt flooring with metal fencing. Interior is a narrow space with dirt flooring and a strong odor of ammonia. Frozen water is available, no food is present.</p>	<p>This dog is very thin at a body condition score of 2/9 on the Purina Scale. Pale pink mucous membranes with CRT of 3 seconds. Grade 2/4 dental disease with moderate plaque and mild swelling of the gum line. Dried nasal discharge. Vulva is mildly swollen, mammary glands actively lactating - pregnant. Mild fur matting of the tail. Mass palpable over the right zygomatic arch (cheek bone) approximately 4 cm in diameter, raised 2 cm from the skull. Mass palpates soft and fluctuant, scarring over the surface. Hypersalivation.</p>	<p>PCV/TS- 39%/8.2, 4DX- negative, Witness pregnancy test-positive, Fecal pending. Chemistry - Total Protein 7.6 g/dL (5.0-7.4) Albumin 2.4 g/dL (2.7-4.4) Globulin 5.2 g/dL (1.6-3.6) AST (SGOT) 13 IU/L (15-66) Calcium 8.6 mg/dL (8.9-11.4) CPK 56 IU/L (59-895). Fine needle aspirate - pending.</p>	<p>Vaccinated (Rabies, DAPP, Bordetella), dewormed, started on flea/tick preventative and heartworm preventative. Provide anti-nausea medication for suspected nausea. Treatment plan for mass on right zygomatic arch pending diagnostics results. Increase nutritional plane for weight gain. Provide grooming. Reassess dental status in 3-6 months to schedule cleaning.</p>
------------------	---	--	---	--	--	--


<p>2038-1B-5</p>		<p>Adult, female, white Samoyed-type dog</p>	<p>Co-housed in a wood building with indoor/outdoor access. Rubber flaps are at the indoor/outdoor entries. The yard facing the house has a concrete floor, metal roof and metal fencing. The yard facing away from the house is frozen dirt flooring with metal fencing. Interior has dirt flooring and in a corner is a wooden box-type structure with 4 low sides and no top. There is a strong odor of ammonia. A bucket of frozen water is available, no food is present.</p>	<p>This dog is thin at a body condition score of 3/9 on the Purina Scale. Grade 3/4 dental disease with moderate tartar and gingivitis. All incisor teeth are worn. Mammary glands and nipple development noted. Dirty fur coat. Matted fur on the left forearm. Overgrown nails.</p>	<p>PCV/TS- 40%/7.0, 4DX- negative, Witness pregnancy test-positive, Fecal pending. CBC/Chemistry pending.</p>	<p>Vaccinated (Rabies, DAPP, Bordetella), dewormed, started on flea/tick preventative and heartworm preventative. Provide grooming and nail trim. Increase nutritional plane for weight gain. Provide dental treatment.</p>
------------------	---	--	--	---	---	---


<p>2038-1B-6</p>		<p>Adult, male white Samoyed-type dog</p>	<p>Co-housed in a wood building with indoor/outdoor access. Rubber flaps are at the indoor/outdoor entries. The yard facing the house has a concrete floor, metal roof and metal fencing. The yard facing away from the house is frozen dirt flooring with metal fencing. Interior has dirt flooring and in a corner is a wooden box-type structure with 4 low sides and no top. There is a strong odor of ammonia. A bucket of frozen water is available, no food is present.</p>	<p>This dog is thin at a body condition score of 3/9 on the Purina Scale. Pale mucous membranes. Grade 1/4 dental disease with moderate calculus and mild gingivitis. Mild generalized muscle wasting. Dry, dirty fur coat. Moderate fur matting particularly of the neck, hindquarters, tail and back of legs. Small amount of fecal staining around region of the anus.</p>	<p>PCV/TS- 43%/6.9, 4DX- negative, Fecal pending.</p>	<p>Vaccinated (Rabies, DAPP, Bordetella), dewormed, started on flea/tick preventative and heartworm preventative. Provide grooming and nail trim. Increase nutritional plane for weight gain. Provide dental treatment. Increase nutritional plane for weight gain. Provide grooming. Dental re-evaluation in 6 months.</p>
------------------	---	---	--	---	---	---


<p>2038-1B-7</p>		<p>Young-adult, female, white Samoyed-type dog</p>	<p>Co-housed in a wood building with indoor/outdoor access. Rubber flaps are at the indoor/outdoor entries. The yard facing the house has a concrete floor, metal roof and metal fencing. The yard facing away from the house is frozen dirt flooring with metal fencing. Interior has dirt flooring and in a corner is a wooden box-type structure with 4 low sides and no top. There is a strong odor of ammonia. A bucket of frozen water is available, no food is present.</p>	<p>This dog is lean at a body condition score of 4/9 on the Purina Scale. Grade 1/4 dental disease with mild calculus. Vulva is mildly swollen with mild active bloody discharge, perivulvar region has dried blood. Left carpus, lumbar area, and elbows have area of red-to-orange discolored fur</p>	<p>PCV/TS- 40%/6.8, 4DX- negative, Witness pregnancy test- negative, Fecal pending.</p>	<p>Vaccinated (Rabies, DAPP, Bordetella), dewormed, started on flea/tick preventative and heartworm preventative. Provide grooming and nail trim. Recheck vaginal discharge in 2 weeks. Reassess dental status in 1 year.</p>
------------------	---	--	--	---	---	---


<p>2038-1B-200</p>		<p>Adult, female, white Samoyed-type dog</p>	<p>Co-housed with indoor/outdoor access. Concrete floor inside with rubber flaps covering entrance to outdoor portion with a dirt floor. Access to 3/4 bucket of frozen water and no access to food.</p>	<p>This dog is thin at a body condition score of 3/9 on the Purina Scale. Grade 1/4 dental disease with mild calculus on teeth, mild inflammation of the gums, possible lesion approximately 1 mm on left aspect of tongue. Nose has a line of depigmented skin with peripheral swelling of lesion. Dirty fur coat with moderate matting of the hips, hind quarters, tail, head, and neck. Overgrown nails.</p>	<p>PCV/TS- %/7.2, 4DX- negative, Witness pregnancy test-negative, Fecal pending.</p>	<p>Vaccinated (Rabies, DAPP, Bordetella), dewormed, started on flea/tick preventative and heartworm preventative. Increase nutritional plane for weight gain. Re-evaluate dental status in 6 months. Provide grooming and nail trim. Recheck nose and tongue lesion - if not resolved treatment plan will be made.</p>
--------------------	---	--	--	---	--	--


<p>2038-1B-201</p>		<p>Geriatric, male, white Samoyed-type dog</p>	<p>Co-housed with indoor/outdoor access. Concrete floor inside with rubber flaps covering entrance to outdoor portion with a dirt floor. Access to 3/4 bucket of frozen water and no access to food.</p>	<p>This dog is very thin at a body condition score of 2/9 on the Purina Scale. Grade 3/4 dental disease with moderate calculus and inflammation of the gums. Both eyes negative for menace response and negative for PLR response. Both eyes have cloudiness and mild increase in tearing - blind. Left testicle approximately 1.5 times larger than right testicle. Moderate generalized muscle wasting. Stiff ambulation and reluctant to walk. Severe fur matting that palpate tight against the skin. One large fecal mat covering anus and perineum. Any produced feces are obstructed by fecal matting covering anus, resulting in compact feces around anus. Once fecal pac was removed, revealed mildly reddened skin around anus. Left ear tip has absent fur. Overgrown nails.</p>	<p>PCV/TS- 43%/7.1, 4DX- negative, CBC/Chem and Fecal pending.</p>	<p>Vaccinated (Rabies, DAPP, Bordetella), dewormed, started on flea/tick preventative and heartworm preventative. Increase nutritional plane for weight gain. Recommend ophthalmology consultation for suspected blindness. Recommend priority dental cleaning. Provide pain control for suspected osteoarthritis. Continue to monitor anus for signs of irritation.</p>
--------------------	---	--	--	--	--	--


<p>2038-1B-202</p>		<p>Adult, female, white Samoyed-type dog</p>	<p>Co-housed with indoor/outdoor access. Concrete floor inside with rubber flaps covering entrance to outdoor portion with a dirt floor. Access to 3/4 bucket of frozen water and no access to food.</p>	<p>This dog is very thin at a body condition score of 2/9 on the Purina Scale. Grade 2/4 dental disease with moderate tartar. Abdomen distended and mammary glands well developed - likely pregnant. Possible disorganized mass of the right caudal mammary gland. Dirty fur coat with large fur mats on the chest and behind the ears. Overgrown nails.</p>	<p>PCV/TS- 33%/7.4, 4DX- negative, Witness pregnancy test- positive, CBC/Chem and Fecal pending.</p>	<p>Vaccinated (Rabies, DAPP, Bordetella), dewormed, started on flea/tick preventative and heartworm preventative. Reassess possible right caudal mammary mass after weaning. Reassess dental status in 6 months. Increase nutritional plane for weight gain.</p>
--------------------	---	--	--	--	--	--


<p>2038-1B-203</p>		<p>Adult, female, white Samoyed-type dog</p>	<p>Co-housed with indoor/outdoor access. Concrete floor inside with rubber flaps covering entrance to outdoor portion with a dirt floor. Access to 3/4 bucket of frozen water and no access to food.</p>	<p>This dog is lean at a body condition score of 4/9 on the Purina Scale. Grade 2/4 dental disease with moderate tartar. Both ear tips healing wounds. Mammary gland development. Reducible umbilical hernia. 2 cm in diameter crust on the upper left side of the neck. Dirty fur coat.</p>	<p>PCV/TS- 47%/8.1, 4DX- negative, Witness pregnancy test-negative, Fecal pending.</p>	<p>Vaccinated (Rabies, DAPP, Bordetella), dewormed, started on flea/tick preventative and heartworm preventative. Provide grooming and nail trim. Clip and clean area of scab on the upper left side of the neck. Recommend surgical repair of reducible umbilical hernia. Reassess dental status in 6 months. Recheck ear tips in 1 week.</p>
--------------------	---	--	--	--	--	--


<p>2038-1B-204</p>		<p>Adult, male, white Samoyed-type dog</p>	<p>Co-housed with indoor/outdoor access. Concrete floor inside with feces and rubber flaps covering entrance to outdoor portion with a concrete floor. Access to 1/4 bucket of frozen water and no access to food.</p>	<p>This dog is thin at a body condition score of 3/9 on the Purina Scale. Grade 2/4 dental disease with moderate tartar. Both ears have mild brown debris. Severe fur matting with plant debris behind the ears, on the body, on legs, and tail. Grade 1/6 heart murmur.</p>	<p>PCV/TS- 49%/7.2, 4DX- negative, CBC/Chem and Fecal pending.</p>	<p>Vaccinated (Rabies, DAPP, Bordetella), dewormed, started on flea/tick preventative and heartworm preventative. Provide grooming. Increase nutritional plane for weight gain. Recheck heart murmur in 1 month. Recheck dental status in 6 months.</p>
--------------------	---	--	--	--	--	---


<p>2038-1B-205</p>		<p>Adult, male, white Samoyed-type dog</p>	<p>Co-housed in a wood building with indoor/outdoor access. Rubber flaps are at the indoor/outdoor entries. The yard facing the house has a concrete floor, metal roof and metal fencing. Interior has dirt flooring and a build-up of feces. There is a strong odor of ammonia. A bucket of frozen water is available. No food is present.</p>	<p>This dog is thin at a body condition score of 3/9 on the Purina Scale. Grade 2/4 dental disease with moderate dental tartar and mild inflammation of the gums. The canine teeth have worn enamel on the back aspect. Scar on the left nares. Matting of fur around the neck and entire trunk of the body. Very matted tail with significant amount of debris. Lick granuloma over the left carpus measuring 1 cm x 2 cm.</p>	<p>PCV/TS- 49%/6.8, 4DX- negative, CBC/Chem and Fecal pending.</p>	<p>Vaccinated (Rabies, DAPP, Bordetella), dewormed, started on flea/tick preventative and heartworm preventative. Reassess dental status in 6 months. Increase nutritional plane for weight gain. Begin oral antibiotics for lick granuloma.</p>
--------------------	---	--	---	---	--	--


<p>2038-1B-206</p>		<p>Adult, male, white Samoyed-type dog</p>	<p>Co-housed in a wood building with indoor/outdoor access. Rubber flaps are at the indoor/outdoor entries. The yard facing the house has a concrete floor, metal roof and metal fencing. Interior has dirt flooring and a build-up of feces. There is a strong odor of ammonia. A bucket of frozen water is available. No food is present.</p>	<p>This dog is lean at a body condition score of 4/9 on the Purina Scale. Grade 1/4 dental disease with mild tartar, particularly on the teeth in the back of the mouth. Mild clear nasal discharge. Mild muscle atrophy. Extensive fur matting with organic debris. Overgrown nails.</p>	<p>PCV/TS- 43%/8.5, 4DX- negative, Fecal pending. CBC - WBC increased at 16.8 (4.0-15.5) eosinophils increased at 8064 (0-1200). Chemistry - TP increased at 8.0 (5.0-7.4) Globulin increased at 5.2 (1.6-3.6)</p>	<p>Vaccinated (Rabies, DAPP, Bordetella), dewormed, started on flea/tick preventative and heartworm preventative. Priority grooming and nail trim. Reassess dental status in 6 months. Reassess respiratory discharge for signs of respiratory infection in 1 week.</p>
--------------------	--	--	---	---	--	---


<p>2038-1B-207</p>		<p>Adult, female, white Samoyed-type dog</p>	<p>Co-housed in a wood building with indoor/outdoor access. Rubber flaps are at the indoor/outdoor entries. The yard facing the house has a concrete floor, metal roof and metal fencing. The yard facing away from the house is frozen dirt flooring with metal fencing. There is a hole under the fence which allows travel between a neighboring dog yard. Interior has dirt flooring and in a corner is a wooden box-type structure with 4 low sides and no top. There is a strong odor of ammonia. A bucket of frozen water is available, no food is present.</p>	<p>This dog is thin at a body condition score of 3/9 on the Purina Scale. Grade 1/4 dental disease with enamel defect on tooth 102 and 103. Mild dental tartar. Nipples are enlarged. Fur mats on the left side of the neck. Scab on the right side of the muzzle. Overgrown nails.</p>	<p>PCV/TS- 41%/7.1, 4DX- negative, Witness pregnancy test-negative, Fecal pending. CBC - WBC increased at 22.5 (4.0-15.5) neutrophils increased 14,850 (2060-10600). Chemistry - unremarkable.</p>	<p>Vaccinated (Rabies, DAPP, Bordetella), dewormed, started on flea/tick preventative and heartworm preventative. Provide nail trim and grooming. Increase nutritional plane for weight gain. Recheck scab on the right side of the muzzle in 1 week. Reassess dental status in 1 year.</p>
--------------------	---	--	--	---	--	---


<p>2038-1B-208</p>		<p>Adult, male, white Samoyed- type dog</p>	<p>Co-housed in a wood building with indoor/outdoor access. Rubber flaps are at the indoor/outdoor entries. The yard facing the house has a concrete floor, metal roof and metal fencing. The yard facing away from the house is frozen dirt flooring with metal fencing. There is a hole under the fence which allows travel between a neighboring dog yard. Interior has dirt flooring and in a corner is a wooden box-type structure with 4 low sides and no top. There is a strong odor of ammonia. A bucket of frozen water is available, no food is present.</p>	<p>This dog is thin at a body condition score of 3/9 on the Purina Scale. Grade 2/4 dental disease moderate tartar and gingivitis. Mats of fur behind the ears and toes. Feces and fur matted around the anus. Mild fur matting on the body. Overgrown nails.</p>	<p>PCV/TS- 43%/7.2, 4DX- negative, CBC/Chem and Fecal pending.</p>	<p>Vaccinated (Rabies, DAPP, Bordetella), dewormed, started on flea/tick preventative and heartworm preventative. Provide grooming and nail trim. Increase nutritional plane for weight gain. Reassess dental disease in 6 months.</p>
--------------------	---	---	--	---	--	--


<p>2038-1B-209</p>		<p>Adult, female, white Samoyed-type dog</p>	<p>Co-housed in a wood building with indoor/outdoor access. Rubber flaps are at the indoor/outdoor entries. The yard facing the house has a concrete floor, metal roof and metal fencing. The yard facing away from the house is frozen dirt flooring with metal fencing. There is a hole under the fence which allows travel between a neighboring dog yard. Interior has dirt flooring and in a corner is a wooden box-type structure with 4 low sides and no top. There is a strong odor of ammonia. A bucket of frozen water is available, no food is present.</p>	<p>This dog is thin at a body condition score of 3/9 on the Purina Scale. Grade 2/4 dental disease with moderate tartar, gingivitis, and halitosis. The left ear has a 0.5 cm in length wound. Umbilical hernia approximately 1 cm in diameter. Fur mats near the ears and matting of fur with debris in tail. Overgrown nails.</p>	<p>PCV/TS- 40%/7.9, 4DX- negative, Witness pregnancy test- negative, CBC/Chem and Fecal pending.</p>	<p>Vaccinated (Rabies, DAPP, Bordetella), dewormed, started on flea/tick preventative and heartworm preventative. Provide grooming and nail trim. Reassess dental status in 1 year. Increase nutritional plane for weight gain. Recheck ear wound in 1 week. Surgical repair of umbilical hernia.</p>
--------------------	---	--	--	---	--	---


<p>2038-1B-210</p>		<p>Adult, male, white Samoyed-type dog</p>	<p>Co-housed in a wood building with indoor/outdoor access. Rubber flaps are at the indoor/outdoor entries. The yard facing the house has a concrete floor, metal roof and metal fencing. The yard facing away from the house has dirt flooring and dug holes with a metal perimeter fence. Interior has dirt flooring and a build-up of feces; one corner of the interior has a low box-like structure with no roof. There is a strong odor of ammonia. Two buckets are present, one is empty, the other has a scant amount of frozen water at the bottom. No food is available.</p>	<p>This dog is thin at a body condition score of 3/9 on the Purina Scale. Grade 2/4 dental disease with moderate tartar. Matted fur on tail. Generalized dirty coat. Both eyes have immature cataracts. Left ear has moderate otitis, right ear has mild otitis. Overgrown nails.</p>	<p>PCV/TS- 46%/6.9, 4DX- negative, Witness pregnancy test-negative. Ear cytology CBC/Chem and Fecal pending.</p>	<p>Vaccinated (Rabies, DAPP, Bordetella), dewormed, started on flea/tick preventative and heartworm preventative. Provide grooming and nail trim. Increase nutritional plane for weight gain. Reassess dental disease and cataract development in 6 months. Treatment plan based on ear cytology results.</p>
--------------------	---	--	---	---	--	---


<p>2038-1B-211</p>		<p>Adult, female, white Samoyed-type dog</p>	<p>Co-housed in a wood building with indoor/outdoor access. Rubber flaps are at the indoor/outdoor entries. The yard facing the house has a concrete floor, metal roof and metal fencing. The yard facing away from the house has dirt flooring and dug holes with a metal perimeter fence. Interior has dirt flooring and a build-up of feces; one corner of the interior has a low box-like structure with no roof. There is a strong odor of ammonia. Two buckets are present, one is empty, the other has a scant amount of frozen water at the bottom. No food is available.</p>	<p>This dog is lean at a body condition score of 4/9 on the Purina Scale. Grade 1/4 dental disease with mild tartar. Enlarged and thickened vulva. Flea dirt present. Fur mats behind ears. Dirt dried into fur. Overgrown nails.</p>	<p>PCV/TS- 40%/7.7, 4DX- negative, Witness pregnancy test-positive, Fecal pending.</p>	<p>Vaccinated (Rabies, DAPP, Bordetella), dewormed, started on flea/tick preventative and heartworm preventative. Provide grooming and nail trim. Reassess dental status in 6 months.</p>
--------------------	---	--	---	---	--	---


<p>2038-1B-212</p>		<p>Adult, female, white Samoyed-type dog</p>	<p>Co-housed in a wood building with indoor/outdoor access. Rubber flaps are at the indoor/outdoor entries. The yard facing the house has a concrete floor, metal roof and metal fencing. The yard facing away from the house has dirt flooring and dug holes with a metal perimeter fence. Interior has dirt flooring and a build-up of feces; one corner of the interior has a low box-like structure with no roof. There is a strong odor of ammonia. Two buckets are present, one is empty, the other has a scant amount of frozen water at the bottom. No food is available.</p>	<p>This dog is thin at a body condition score of 3/9 on the Purina Scale. Grade 1/4 dental disease with mild tartar. Prominent mammary glands. Fur mats behind the ears, along the back, along the back of hind legs and tail. Fecal material matted into perianal area and right thigh. Overgrown nails.</p>	<p>PCV/TS- 49%/6.2, 4DX- negative, Witness pregnancy test-pending, CBC/Chem and Fecal pending.</p>	<p>Vaccinated (Rabies, DAPP, Bordetella), dewormed, started on flea/tick preventative and heartworm preventative. Provide grooming and nail trim. Reassess dental status in 6 months.</p>
--------------------	---	--	---	---	--	---


<p>2038-1B-213</p>		<p>Adult, male, white Samoyed-type dog</p>	<p>Co-housed in a wood building with indoor/outdoor access. Rubber flaps are at the indoor/outdoor entries. The yard facing the house has a concrete floor, metal roof and metal fencing. The yard facing away from the house has dirt flooring and dug holes with a metal perimeter fence. Interior has dirt flooring and a build-up of feces; one corner of the interior has a low box-like structure with no roof. There is a strong odor of ammonia. Two buckets are present, one is empty, the other has a scant amount of frozen water at the bottom. No food is available.</p>	<p>This dog is lean at a body condition score of 4/9 on the Purina Scale. Redundant skin (skin tag) at the inner aspect of the right eye. Episcleral injection of the right eye. Grade 2/4 dental disease with moderate tartar. Matted fur on the front legs, thighs, and tail. Flea dirt present. Dirty fur coat. Mild interdigital irritation (erythematous) of the front feet. Overgrown nails.</p>	<p>PCV/TS- 46%/6.7, 4DX- negative, and Fecal pending. Fluorescein staining of the right eye - negative.</p>	<p>Vaccinated (Rabies, DAPP, Bordetella), dewormed, started on flea/tick preventative and heartworm preventative. Provide nail trim and grooming. Recheck skin tag on right eye margin in 1 month. Recheck interdigital erythema after grooming. Recheck dental status in 6 months.</p>
--------------------	---	--	---	--	---	---


<p>2038-1B-214</p>		<p>Adult, female, white Samoyed-type dog</p>	<p>Co-housed in a wood building with indoor/outdoor access. Rubber flaps are at the indoor/outdoor entries. The yard facing the house has a concrete floor, metal roof and metal fencing. The yard facing away from the house has dirt flooring and dug holes with a metal perimeter fence. Interior has dirt flooring and a build-up of feces; one corner of the interior has a low box-like structure with no roof. There is a strong odor of ammonia. Two buckets are present, one is empty, the other has a scant amount of frozen water at the bottom. No food is available.</p>	<p>This dog is lean at a body condition score of 4/9 on the Purina Scale. Grade 1/4 dental disease with tartar on tooth 108 and 208. Sedated for examination. 2 inch fur mat noted under right ear. Overgrown nails.</p>	<p>PCV/TS- 39%/7.2, 4DX- negative, Witness pregnancy test-negative. Fecal pending. CBC - WBC increased at 26 (4.0-15.5). Chemistry - Globulin increased at 3.9 (1.6-3.6)</p>	<p>Vaccinated (Rabies, DAPP, Bordetella), dewormed, started on flea/tick preventative and heartworm preventative. Recommend grooming and nail trim. Reassess dental disease in 1 year.</p>
--------------------	---	--	---	--	--	--


<p>2038-1B-215</p>		<p>Adult, female, white Samoyed-type dog</p>	<p>Co-housed in a wood building with indoor/outdoor access. Rubber flaps are at the indoor/outdoor entries. The yard facing the house has a concrete floor, metal roof and metal fencing. The yard facing away from the house has dirt flooring and dug holes with a metal perimeter fence. A mature tree is down in the yard altering the integrity of a fence separating another dog yard. Interior has dirt flooring and a build-up of feces; one corner of the interior has a low box-like structure with no roof. There is a strong odor of ammonia. Two buckets are present, one is empty, the other has a frozen water. No food is available.</p>	<p>This dog is thin at a body condition score of 3/9 on the Purina Scale. Grade 1/4 dental disease with mild tartar and worn incisors. Left lateral canthus has a scar. Caudal mammary mass approximately 5 cm in diameter, lobulated. Dirty fur coat with feces around anus and backs of legs. Overgrown nails. Small amount of ceruminous debris in both ears.</p>	<p>PCV/TS- 49%/8.1, 4DX- negative, Witness pregnancy test-positive, CBC/Chem and Fecal pending. Fine need aspirate of mammary mass.</p>	<p>Vaccinated (Rabies, DAPP, Bordetella), dewormed, started on flea/tick preventative and heartworm preventative. Provide nail trim, grooming, and ear cleaning. Increase nutritional plane for weight gain. Recheck dental disease in 1 year. Treatment plan based on fine needle aspirate of mammary gland mass.</p>
--------------------	---	--	--	--	---	--


<p>2038-1B-216</p>		<p>Adult, female, white Samoyed-type dog</p>	<p>Co-housed in a wood building with indoor/outdoor access. Rubber flaps are at the indoor/outdoor entries. The yard facing the house has a concrete floor, metal roof and metal fencing. The yard facing away from the house has dirt flooring and dug holes with a metal perimeter fence. A mature tree is down in the yard altering the integrity of a fence separating another dog yard. Interior has dirt flooring and a build-up of feces; one corner of the interior has a low box-like structure with no roof. There is a strong odor of ammonia. Two buckets are present, one is empty, the other has frozen water. No food is available.</p>	<p>This dog is lean at a body condition score of 4/9 on the Purina Scale. Grade 2/4 dental disease with mild to moderate tartar and wear on canines. Mild ocular discharge. Grade 3-4/6 heart murmur. Matting of fur behind the ears, caudal thighs, legs, and tail. Flea dirt present. Overgrown nails.</p>	<p>PCV/TS- 42%/8.0, 4DX- negative, Fecal pending.</p>	<p>Vaccinated (Rabies, DAPP, Bordetella), dewormed, started on flea/tick preventative and heartworm preventative. Reassess dental status in 6 months. Provide grooming and nail trim. Recommend cardiology consultation. Monitor ocular discharge.</p>
--------------------	---	--	--	--	---	--


<p>2038-1B-217</p>		<p>Adult, female, white Samoyed-type dog</p>	<p>Co-housed in a wood building with indoor/outdoor access. Rubber flaps are at the indoor/outdoor entries. The yard facing the house has a concrete floor, metal roof and metal fencing. The yard facing away from the house has dirt flooring and dug holes with a metal perimeter fence. A mature tree is down in the yard altering the integrity of a fence separating another dog yard. Interior has dirt flooring and a build-up of feces; one corner of the interior has a low box-like structure with no roof. There is a strong odor of ammonia. Two buckets are present, one is empty, the other has a frozen water. No food is available.</p>	<p>This dog is lean at a body condition score of 4/9 on the Purina Scale. Grade 1/4 dental disease with mild tartar present. Grade 1/6 left-sided heart murmur. Strong odor of urine from coat. Multiple large mats on the back and caudal thighs. Flea dirt present. Overgrown nails.</p>	<p>PCV/TS- 40%/7.1, 4DX- negative, Witness pregnancy test- negative, CBC/Chem and Fecal pending. Urinalysis - U/A free catch sample USG 1.041 Protein TRACE WBC 4-10 HPF (0-3/HPF) Struvite Crystals 2-3 HPF Bacteria Rods 26-50/hpf</p>	<p>Vaccinated (Rabies, DAPP, Bordetella), dewormed, started on flea/tick preventative and heartworm preventative. For urinary tract infection begin enrofloxacin at 20 mg/kg SID X 5 days and recheck U/A in one week from end of antibiotic. Reassess dental status in 6 months. Recheck heart murmur in 1 month. Provide grooming and nail trim.</p>
--------------------	---	--	--	--	--	--


<p>2038-1B-218</p>		<p>Adult, male, white Samoyed-type dog</p>	<p>Co-housed in a wood building with indoor/outdoor access. Rubber flaps are at the indoor/outdoor entries. The yard facing the house has a concrete floor, metal roof and metal fencing. The yard facing away from the house has dirt flooring and dug holes with a metal perimeter fence. A mature tree is down in the yard altering the integrity of a fence separating another dog yard. Interior has dirt flooring and a build-up of feces; one corner of the interior has a low box-like structure with no roof. There is a strong odor of ammonia. Two buckets are present, one is empty, the other has a frozen water. No food is available.</p>	<p>This dog is thin to very thin at a body condition score of 2.5/9 on the Purina Scale. Grade 3/4 dental disease with heavy calculus on all teeth. All lower incisor teeth are worn. Diffuse gingival inflammation. Mild generalized muscle wasting. Fur mat at the base of the right ear approximately 15 cm in length. Dorsal nose has some loss of pigmentation with mild hyperkeratosis. Dirty fur coat with severe matting throughout coat including head, limbs, neck, and trunk. Dried fecal material around the anus. Mild redness around the anus. Overgrown nails.</p>	<p>PCV/TS- 42%/6.8, 4DX- negative, CBC/Chem and Fecal pending.</p>	<p>Vaccinated (Rabies, DAPP, Bordetella), dewormed, started on flea/tick preventative and heartworm preventative. Improve nutritional plane for weight gain. Recommend a dental cleaning within one month. High priority for grooming and nail trim. Monitor nose and consider dermatology consultation.</p>
--------------------	---	--	--	---	--	--


<p>2038-1B-220</p>		<p>Adult, male white Samoyed- type dog</p>	<p>Co-housed in a wood building with indoor/outdoor access. Rubber flaps are at the indoor/outdoor entries. The yard facing the house has a concrete floor, metal roof and metal fencing. The yard facing away from the house has dirt flooring and dug holes with a metal perimeter fence. A mature tree is down in the neighboring yard altering the integrity of a fence separating another dog yard. Interior has dirt flooring and a build-up of feces; one corner of the interior has a low box-like structure with no roof. There is a strong odor of ammonia. Bucket with frozen water present, holes in the top ice layer allow access to unfrozen water. No food is available.</p>	<p>This dog is thin at a body condition score of 3/9 on the Purina Scale. Mildly dehydrated (5-7%). Grade 2/4 dental disease with wear on the tips of tooth 104 and 204. Generalized mild muscle wasting. No tail present. Matting of fur behind ears and top of the neck. Severe matted around anus and back of thighs with fecal debris. Mild perianal dermatitis. Overgrown nails.</p>	<p>PCV/TS- 39%/8.3, 4DX- negative, CBC/Chem and Fecal pending.</p>	<p>Vaccinated (Rabies, DAPP, Bordetella), dewormed, started on flea/tick preventative and heartworm preventative. Increase nutritional plane for weight gain. Provide grooming and nail trim. Provide oral antibiotic for 2 weeks for dermatitis. Recheck dermatitis.</p>
--------------------	---	--	--	---	--	---


<p>2038-1B-221</p>		<p>Adult, female, white Samoyed- type dog</p>	<p>Co-housed in a wood building with indoor/outdoor access. Rubber flaps are at the indoor/outdoor entries. The yard facing the house has a concrete floor, metal roof and metal fencing. The yard facing away from the house has dirt flooring and dug holes with a metal perimeter fence. A mature tree is down in the neighboring yard altering the integrity of a fence separating another dog yard. Interior has dirt flooring and a build-up of feces; one corner of the interior has a low box-like structure with no roof. There is a strong odor of ammonia. Bucket with frozen water present, holes in the top ice layer allow access to unfrozen water. No food is available.</p>	<p>This dog is lean at a body condition score of 4/9 on the Purina Scale. Grade 2/4 dental disease with moderate calculus. Developed mammary glands. Dirty, dry fur coat. Left ear tip has fur thinning with black debris.</p>	<p>PCV/TS- 49%/8.0, 4DX- negative, and Fecal pending.</p>	<p>Vaccinated (Rabies, DAPP, Bordetella), dewormed, started on flea/tick preventative and heartworm preventative. Provide grooming. Recommend for a dental cleaning in the next 6 months.</p>
--------------------	---	---	--	--	---	---


<p>2038-1B-222</p>		<p>Adult, male, white Samoyed-type dog</p>	<p>Co-housed in a wood building with indoor/outdoor access. Rubber flaps are at the indoor/outdoor entries. The yard facing the house has a concrete floor, metal roof and metal fencing. The yard facing away from the house has dirt flooring and dug holes with a metal perimeter fence. A mature tree is down in the neighboring yard altering the integrity of a fence separating another dog yard. Interior has dirt flooring and a build-up of feces; one corner of the interior has a low box-like structure with no roof. There is a strong odor of ammonia. Bucket with frozen water present, holes in the top ice layer allow access to unfrozen water. No food is available.</p>	<p>This dog is very thin at a body condition score of 2/9 on the Purina Scale. Grade 3/4 dental disease with heavy tartar and gingivitis. The right ear tip has a 2 cm area of alopecia and reddening. Mild nasal pigmentation and hyperkeratosis. Mild muscle wasting. Flea dirt present. Caked debris in interdigital space. Mild pododermatitis. Diffuse small fur mats. Overgrown nails.</p>	<p>PCV/TS- 37%/7.3, 4DX- negative, Fecal pending. CBC - WBC 19.8 (4.0-15.5) Eosinophils 5,544 /uL (0-1200). Chemistry - Albumin 2.6 g/dL (2.7-4.4) Globulin 3.7 g/dL (1.6-3.6).</p>	<p>Vaccinated (Rabies, DAPP, Bordetella), dewormed, started on flea/tick preventative and heartworm preventative. Increase nutritional plane for weight gain. Provide grooming and nail trim. Recommend dental cleaning. Reassess pododermatitis after grooming.</p>
--------------------	---	--	--	--	---	--


<p>2038-1B-223</p>		<p>Adult, female, white Samoyed-type dog</p>	<p>Co-housed in a wood building with indoor/outdoor access. Rubber flaps are at the indoor/outdoor entries. The yard facing the house has a concrete floor, metal roof and metal fencing. The yard facing away from the house has dirt flooring and dug holes with a metal perimeter fence. A mature tree is down in the neighboring yard altering the integrity of a fence separating another dog yard. Interior has dirt flooring and a build-up of feces; one corner of the interior has a low box-like structure with no roof. There is a strong odor of ammonia. Bucket with frozen water present, holes in the top ice layer allow access to unfrozen water. No food is available.</p>	<p>This dog is very thin at a body condition score of 2/9 on the Purina Scale. Grade 1/4 dental disease with moderate tartar over tooth 108 and 208. Muscle loss. Fur matting with dirt, debris, and feces. Overgrown nails.</p>	<p>PCV/TS- 39%/8.2, 4DX- negative, CBC/Chem and Fecal pending.</p>	<p>Vaccinated (Rabies, DAPP, Bordetella), dewormed, started on flea/tick preventative and heartworm preventative. Recommend reassessing dental status in 6 months. Increase nutritional plane for weight gain.</p>
--------------------	---	--	--	--	--	--


<p>2038-1B-224</p>		<p>Adult, female, white Samoyed-type dog</p>	<p>Co-housed in a wood building with indoor/outdoor access. Rubber flaps are at the indoor/outdoor entries. The yard facing the house has a concrete floor, metal roof and metal fencing. The yard facing away from the house has dirt flooring and dug holes with a metal perimeter fence. A mature tree is down in the neighboring yard altering the integrity of a fence separating another dog yard. Interior has dirt flooring and a build-up of feces; one corner of the interior has a low box-like structure with no roof. There is a strong odor of ammonia. Bucket with frozen water present, holes in the top ice layer allow access to unfrozen water. No food is available.</p>	<p>This dog is very thin at a body condition score of 2/9 on the Purina Scale. Grade 2/4 dental disease, tartar and gingivitis present. Generalized muscle loss. Overgrown nails.</p>	<p>PCV/TS- 49%/7.9, 4DX- negative, Witness pregnancy test-positive, CBC/Chem and Fecal pending.</p>	<p>Vaccinated (Rabies, DAPP, Bordetella), dewormed, started on flea/tick preventative and heartworm preventative. Increase nutritional plane for weight gain. Dental consult in 3 months. Trim nails.</p>
--------------------	---	--	--	---	---	---


<p>2038-1B-225</p>		<p>Adult, female, white Samoyed-type dog</p>	<p>Co-housed in a wood building with indoor/outdoor access. Rubber flaps are at the indoor/outdoor entries. The yard facing the house has a concrete floor, metal roof and metal fencing. The yard facing away from the house has dirt flooring and dug holes with a metal perimeter fence. A mature tree is down in the yard altering the integrity of a fence separating another dog yard. Interior has dirt flooring and a build-up of feces; one corner of the interior has a low box-like structure with no roof. There is a strong odor of ammonia. Bucket with frozen water present, holes in the top ice layer allow access to unfrozen water. No food is available.</p>	<p>This dog is lean at a body condition score of 4/9 on the Purina Scale. Pyrexia (103.6). Grade 2/4 dental disease with moderate dental calculus and mild gingivitis. Both ears have mild waxy brown debris. Moderate fur matting at the base of both ears and the tail. Dirty dry fur coat. Overgrown nails.</p>	<p>PCV/TS- 40%/8.2, 4DX- negative, Witness pregnancy test-negative, Fecal pending.</p>	<p>Vaccinated (Rabies, DAPP, Bordetella), dewormed, started on flea/tick preventative and heartworm preventative. Recheck temperature. Recommend a behavior consultation. Recommend a dental within 1 month. Recommend grooming and nail trim.</p>
--------------------	---	--	--	--	--	--


<p>2038-1B-226</p>		<p>Young-adult, female, white Samoyed-type dog</p>	<p>Co-housed in a wood building with indoor/outdoor access. Rubber flaps are at the indoor/outdoor entries. The yard facing the house has a concrete floor, metal roof and metal fencing. The yard facing away from the house has dirt flooring and dug holes with a metal perimeter fence. A mature tree is down in the yard altering the integrity of a fence separating another dog yard. Interior has dirt flooring and a build-up of feces; one corner of the interior has a low box-like structure with no roof. There is a strong odor of ammonia. Bucket with frozen water present, holes in the top ice layer allow access to unfrozen water. No food is available.</p>	<p>This dog is very thin at a body condition score of 2/9 on the Purina Scale. Grade 2/4 dental disease with mild to moderate tartar and mild gingivitis. Above tooth 208 on the gum line is a laceration. Dirty, significantly matted fur coat especially around the head, tail, neck and rear legs. Flea dirt present.</p>	<p>PCV/TS- 33%/8.1, 4DX- negative, Witness Pregnancy test-positive, CBC/Chem and Fecal pending.</p>	<p>Vaccinated (Rabies, DAPP, Bordetella), dewormed, started on flea/tick preventative and heartworm preventative. Provide grooming and nail trim. Recommend dental assessment and cleaning. Increase nutritional plane for weight gain.</p>
--------------------	---	--	--	--	---	---


<p>2038-1B-227</p>		<p>Adult, male, white Samoyed-type dog</p>	<p>Co-housed in a wood building with indoor/outdoor access. Rubber flaps are at the indoor/outdoor entries. The yard facing the house has a concrete floor, metal roof and metal fencing. The yard facing away from the house has dirt flooring and dug holes with a metal perimeter fence. A mature tree is down in the yard altering the integrity of a fence separating yard from both neighboring dog yards. Interior has dirt flooring and a build-up of feces; one corner of the interior has a low box-like structure with no roof. There is a strong odor of ammonia. Two empty buckets are present with no water or food available.</p>	<p>This dog is thin at a body condition score of 3/9 on the Purina Scale. Grade 2/4 dental disease with moderate to heavy tartar. Epulis growth over right premolar 2. Grade 1/6 left sided heart murmur. No palpable testicles in scrotum. Mild muscle wasting diffusely with possible thickening of stifle. Flea dirt present. Numerous fur mats behind ears and on body. Legs have dried debris within the fur. Odor of ammonia from fur coat. Interdigital debris and dirt on all feet. Feces matted into perianal region. Collar matted into fur. 1 cm x 1 cm round mobile subcutaneous mass on the left tarsus. Overgrown nails.</p>	<p>PCV/TS-42 %/6.5, 4DX-negative, Aural cytology-negative, CBC/Chem and Fecal pending. Fine need aspirate of left tarsal mass pending.</p>	<p>Vaccinated (Rabies, DAPP, Bordetella), dewormed, started on flea/tick preventative and heartworm preventative. Increase nutritional plane for weight gain. Based on results of fine needle aspirate of mass on left leg treatment plan. Recheck dental status in 6 months. Recheck heart murmur in 1 month.</p>
--------------------	---	--	--	--	--	--


<p>2038-1B-228</p>		<p>Adult, female, white Samoyed-type dog</p>	<p>Co-housed in a wood building with indoor/outdoor access. Rubber flaps are at the indoor/outdoor entries. The yard facing the house has a concrete floor, metal roof and metal fencing. The yard facing away from the house has dirt flooring and dug holes with a metal perimeter fence. A mature tree is down in the yard altering the integrity of a fence separating yard from both neighboring dog yards. Interior has dirt flooring and a build-up of feces; one corner of the interior has a low box-like structure with no roof. There is a strong odor of ammonia. Two empty buckets are present with no water or food available.</p>	<p>This dog is thin in condition at a body condition score of 3/9 on the Purina Scale. Grade 2/4 dental disease with minimal calculus, diffuse gingival inflammation, multiple fractured teeth with tertiary dentin visible. Signs of liquid stool around anus with mild erythema of the anus. Mammary development with small amount of green-brown vaginal discharge. Mild muscle wasting. Dirty, dry fur coat with diffuse mild to moderate matting of fur. Laceration on the right ear measuring approximately 1 cm in length. Overgrown nails.</p>	<p>PCV/TS- 49%/7.6, 4DX- negative, Witness pregnancy test-positive, Vaginal cytology pending. CBC/Chem and Fecal pending.</p>	<p>Vaccinated (Rabies, DAPP, Bordetella), dewormed, started on flea/tick preventative and heartworm preventative. Increase nutritional plane for weight gain. Recommend priority dental evaluation and cleaning. Recommend grooming and nail trim. Treatment plan based on vaginal cytology results. Begin a 1 week course of probiotics for diarrhea. Clean ear laceration with chlorhexidine solution.</p>
--------------------	---	--	--	--	---	--


<p>2038-1B-229</p>		<p>Adult, female, white Samoyed-type dog</p>	<p>Co-housed in a wood building with indoor/outdoor access. Rubber flaps are at the indoor/outdoor entries. The yard facing the house has a concrete floor, metal roof and metal fencing. The yard facing away from the house has dirt flooring and dug holes with a metal perimeter fence. A mature tree is down in the yard altering the integrity of a fence separating yard from both neighboring dog yards. Interior has dirt flooring and a build-up of feces; one corner of the interior has a low box-like structure with no roof. There is a strong odor of ammonia. Two empty buckets are present with no water or food available.</p>	<p>This dog is thin in condition at a body condition score of 3/9 on the Purina Scale. Grade 2/4 dental disease with moderate calculus. Both eyes have mild dry brown debris and increase tear production. Mild generalized muscle wasting. Matting of the fur behind each of the legs. Large volume of dried dirt on the underside of the body. Overgrown nails.</p>	<p>PCV/TS- 49%/6.9, 4DX- negative, Witness pregnancy test-negative. Fecal pending.</p>	<p>Vaccinated (Rabies, DAPP, Bordetella), dewormed, started on flea/tick preventative and heartworm preventative. Increase nutritional plane for weight gain. Recommend priority dental evaluation and cleaning. Recommend grooming and nail trim. Recommend behavior consultation.</p>
--------------------	---	--	--	---	--	---


<p>2038-1B-300</p>		<p>Geriatric, female, white Samoyed-type dog</p>	<p>Co-housed in a wood building with indoor/outdoor access. Rubber flaps are at the indoor/outdoor entries. The yard facing the house has a concrete floor, metal roof and metal fencing. The yard facing away from the house has dirt flooring and dug holes with a metal perimeter fence. A mature tree is down in the neighboring yard altering the integrity of a fence separating another dog yard. Interior has dirt flooring and a build-up of feces; one corner of the interior has a low box-like structure with no roof. There is a strong odor of ammonia. A bucket has scant frozen water. No food is available.</p>	<p>This dog is very thin at a body condition score of 2/9 on the Purina Scale. Both eyes have mucoid discharge with dried discharge around each eye. Grade 2/4 dental disease with tartar and gingivitis present. All incisor teeth are worn. The 3rd mammary gland on the right side has a 4 cm x 2.5 cm multi-lobulated, freely moveable mass. Muscle loss associated with body score. Severe fur matting interfering with ability to ambulate. Overgrown nails. Pain associated with eyes and feet.</p>	<p>PCV/TS- 42%/6.9, 4DX-negative, Witness pregnancy test- negative, CBC - WBC increased at 26.8 (4.0-15.5) Neutrophils: 18.2 (2-10.6) monocytes and eosinophils also increased (2-4X). Fecal pending. Schirmer Tear Test - both eyes 3. Fluorescein Stain: both eyes negative. Fine needle aspirate of right mammary mass-pending. Urinalysis - bacteria, white blood cells present.</p>	<p>Vaccinated (Rabies, DAPP, Bordetella), dewormed, started on flea/tick preventative and heartworm preventative. Provide treatment for dry eye in both eyes. Provide treatment plan based on urinalysis results. Provide treatment plan based on results of mammary mass fine needle aspirate. Increase nutritional plane for weight gain.</p>
--------------------	---	--	--	--	--	---


<p>2038-1B-301</p>		<p>Adult, female, white Samoyed-type dog</p>	<p>Co-housed in a wood building with indoor/outdoor access. Rubber flaps are at the indoor/outdoor entries. The yard facing the house has a concrete floor, metal roof and metal fencing. The yard facing away from the house has dirt flooring and dug holes with a metal perimeter fence. A mature tree is down in the neighboring yard altering the integrity of a fence separating another dog yard. Interior has dirt flooring and a build-up of feces; one corner of the interior has a low box-like structure with no roof. There is a strong odor of ammonia. A bucket has scant frozen water. No food is available.</p>	<p>This dog is thin at a body condition score of 3/9 on the Purina Scale. Grade 1/4 dental disease with mild plaque. Worn incisor teeth have tertiary dentin exposure. Minimal matting at the base of ears. Overgrown nails.</p>	<p>PCV/TS- 42%/7.9, 4DX-negative, Witness pregnancy test-negative, CBC/Chem pending. Fecal negative.</p>	<p>Vaccinated (Rabies, DAPP, Bordetella), dewormed, started on flea/tick preventative and heartworm preventative. Provide with nail trim and grooming. Nutritional management and recheck weight.</p>
--------------------	---	--	--	--	--	---


<p>2038-1B-302</p>		<p>Young-adult, female, white Samoyed-type dog</p>	<p>Co-housed in a wood building with indoor/outdoor access. Rubber flaps are at the indoor/outdoor entries. The yard facing the house has a concrete floor, metal roof and metal fencing. The yard facing away from the house has dirt flooring and dug holes with a metal perimeter fence. A mature tree is down in the neighboring yard altering the integrity of a fence separating another dog yard. Interior has dirt flooring and a build-up of feces; one corner of the interior has a low box-like structure with no roof. There is a strong odor of ammonia. A bucket has scant frozen water. No food is available.</p>	<p>This dog is very thin at a body condition score of 2/9 on the Purina Scale. Grade 1/4 dental disease with mild calculus and gingival inflammation. Moderate generalized muscle wasting. Dirty fur coat with minimal fur matting. Both ear tips have small 2 cm area of alopecia. Overgrown nails.</p>	<p>PCV/TS- 49%/6.6, 4DX- negative, Witness pregnancy test- negative, CBC/Chem and Fecal pending.</p>	<p>Vaccinated (Rabies, DAPP, Bordetella), dewormed, started on flea/tick preventative and heartworm preventative. Increase nutritional plane for weight gain. Recheck weight weekly for 3 weeks. Provide grooming and nail trim.</p>
--------------------	---	--	--	--	--	--


<p>2038-1B-303</p>		<p>Young-adult, male, white Samoyed-type dog</p>	<p>Co-housed in a wood building with indoor/outdoor access. Rubber flaps are at the indoor/outdoor entries. The yard facing the house has a concrete floor, metal roof and metal fencing. The yard facing away from the house has dirt flooring and dug holes with a metal perimeter fence. A mature tree is down in the neighboring yard altering the integrity of a fence separating another dog yard. Interior has dirt flooring and a build-up of feces; one corner of the interior has a low box-like structure with no roof. There is a strong odor of ammonia. A bucket has scant frozen water. No food is available.</p>	<p>This dog is thin to very thin at a body condition score of 2.5/9 on the Purina Scale. Grade 1/4 dental disease. Left ear canal had moderate waxy brown debris with mild erythema. Moderate generalized muscle wasting. Moderate to severe fur matting throughout fur coat. Near left ear base is a 2 inch diameter region of fur loss with scab. Skin lesion on the left cheek has a 2 inch diameter crusted dermatitis. Overgrown nails.</p>	<p>PCV/TS- 43%/7.1, 4DX- negative, Ear cytology and CBC/Chem pending. Fecal negative.</p>	<p>Vaccinated (Rabies, DAPP, Bordetella), dewormed, started on flea/tick preventative and heartworm preventative. Moderate to high priority for grooming and nail trim. Increase nutritional plane for weight gain, recheck weight in 2 weeks. Recommend a behavior evaluation for anxiolytic medications. Recheck skin in 2 weeks, if dermatitis has not resolved start course of oral antibiotics. Treatment plan based on ear cytology results.</p>
--------------------	---	--	--	--	---	--


<p>2038-1B-304</p>		<p>Young-adult, female, white Samoyed-type dog</p>	<p>Co-housed in a wood building with indoor/outdoor access. Rubber flaps are at the indoor/outdoor entries. The yard facing the house has a concrete floor, metal roof and metal fencing. The yard facing away from the house has dirt flooring and dug holes with a metal perimeter fence. A mature tree is down in the neighboring yard altering the integrity of a fence separating another dog yard. Interior has dirt flooring and a build-up of feces; one corner of the interior has a low box-like structure with no roof. There is a strong odor of ammonia. A bucket has scant frozen water. No food is available.</p>	<p>This dog is very thin at a body condition score of 2/9 on the Purina Scale. Grade 1/4 dental disease with mild tartar. Dirty, severely matted fur coat. Feces present around the anus. Punctate scar on the bridge of nose. Overgrown nails.</p>	<p>PCV/TS- 40%/7.1, 4DX- negative, CBC/Chem and Fecal pending.</p>	<p>Vaccinated (Rabies, DAPP, Bordetella), dewormed, started on flea/tick preventative and heartworm preventative. Provide grooming and nail trim. Increase nutritional plane for weight gain. Recheck dental status within 6 months.</p>
--------------------	---	--	--	---	--	--


<p>2038-1B-305</p>		<p>Young-adult, female, white Samoyed-type dog</p>	<p>Co-housed in a wood building with indoor/outdoor access. Rubber flaps are at the indoor/outdoor entries. The yard facing the house has a concrete floor, metal roof and metal fencing. The yard facing away from the house has dirt flooring and dug holes with a metal perimeter fence. A mature tree is down in the neighboring yard altering the integrity of a fence separating another dog yard. Interior has dirt flooring and a build-up of feces; one corner of the interior has a low box-like structure with no roof. There is a strong odor of ammonia. A bucket has scant frozen water. No food is available.</p>	<p>This dog is lean at a body condition score of 4/9 on the Purina Scale. Scant brown ocular discharge with no presence of inflammation. Grade 1/4 dental disease with mild calculus and gingival inflammation. Dry, dirty fur coat, moderate matting concentrated over the hind quarters and tail. Nails are overgrown.</p>	<p>PCV/TS- 47%/7.6, 4DX- negative, Witness pregnancy test-negative, Fecal pending.</p>	<p>Vaccinated (Rabies, DAPP, Bordetella), dewormed, started on flea/tick preventative and heartworm preventative. Recommend sedated grooming and nail trim. Recommend behavior assessment for possible anxiolytic.</p>
--------------------	---	--	--	--	--	--


<p>2038-1B-306</p>		<p>Geriatric, male, white Samoyed-type dog</p>	<p>Co-housed in a wood building with indoor/outdoor access. Rubber flaps are at the indoor/outdoor entries. The yard facing the house has a concrete floor, metal roof and metal fencing. The yard facing away from the house has dirt flooring and dug holes with a metal perimeter fence. A mature tree is down in the yard altering the integrity of a fence separating another dog yard. Interior has dirt flooring and a build-up of feces; one corner of the interior has a low box-like structure with no roof. There is a strong odor of ammonia. There is frozen water available. No food is available.</p>	<p>This dog is emaciated at a body condition score of 1/9 on the Purina Scale. He is ~ 5-7% dehydrated with tacky mm, and a depressed mentation. Grade 3/4 dental disease with heavy calculus. Both ears have mild waxy debris. Patient is blind (negative for menace response, absent PLR, both eyes have generalized hazy eyes consistent with lenticular sclerosis. Generalized muscle wasting. Severe diffuse matting of whole body. Over right ilium is an oblong full thickness wound with crusting and active drainage of exudative serosanguineous fluid. Wound is approximately 4 cm wide by 3 mm long. Tail is approximately 12 cm long and has an encircling wound that extends approximately 10 cm along the top of the tail head. The wound is caked with fur and debris with actively draining serosanguineous fluid. Large crusting is present underneath the tail with ulceration. The patient is painful on gentle manipulation. Moderately overgrown nails.</p>	<p>PCV/TS- 49%/7.1, 4DX- negative, Urinalysis - 2 + protein. CBC/Chem and Fecal pending. Radiographs pending. Necropsy pending.</p>	<p>Vaccinated (Rabies, DAPP, Bordetella), dewormed, started on flea/tick preventative and heartworm preventative. Patient was humanely euthanized due to grave prognosis.</p>
--------------------	---	--	--	---	---	---


<p>2038-1B-307</p>		<p>Adult, female, white Samoyed-type dog</p>	<p>Co-housed in a wood building with indoor/outdoor access. Rubber flaps are at the indoor/outdoor entries. The yard facing the house has a concrete floor, metal roof and metal fencing. The yard facing away from the house has dirt flooring and dug holes with a metal perimeter fence. Interior has dirt flooring and a build-up of feces; one corner of the interior has a low box-like structure with no roof. There is a strong odor of ammonia. There is frozen water available. No food is available.</p>	<p>This dog is lean at a body condition score of 4/9 on the Purina Scale. Grade 2/4 dental disease with diffuse gingival inflammation and moderate calculus accumulation. Developed mammary chains. Fur coat is dry and dirty with moderate to severe fur matting throughout. Fur mats most notable on the neck and region of the anus. Alopecia noted under collar (after removal), scar present under collar measuring 3 cm wide by 10 cm in length. Nails are overgrown.</p>	<p>PCV/TS-48 %/7.1. 4DX- negative. Witness pregnancy test-negative. Fecal pending.</p>	<p>Vaccinated (Rabies, DAPP, Bordetella), dewormed, started on flea/tick preventative and heartworm preventative. Recommend dental cleaning within the next 3-6 months. Moderate priority for grooming and nail trim. Recommend behavioral assessment.</p>
--------------------	---	--	---	---	--	--


<p>2038-1B-308</p>		<p>Adult, female, white Samoyed-type dog</p>	<p>Co-housed in a wood building with indoor/outdoor access. Rubber flaps are at the indoor/outdoor entries. The yard facing the house has a concrete floor, metal roof and metal fencing. The yard facing away from the house has dirt flooring and dug holes with a metal perimeter fence. Interior has dirt flooring and a build-up of feces; one corner of the interior has a low box-like structure with no roof. There is a strong odor of ammonia. There is frozen water available. No food is available.</p>	<p>This dog is of ideal body condition at a score of 5/9 on the Purina Scale. Grade 2/4 dental disease with moderate tartar. Left eye has corneal pigmentation. Right eye has cataract. Slightly doughy abdomen on palpation. Short tail with no evidence of recent trauma. Interdigital discharge and redness. Flea dirt present. Overgrown nails.</p>	<p>PCV/TS- 43%/8.2. 4DX- negative. Witness pregnancy test-negative. Ear cytology negative. CBC/Chem and Fecal pending.</p>	<p>Vaccinated (Rabies, DAPP, Bordetella), dewormed, started on flea/tick preventative and heartworm preventative. Provide grooming and nail trim. Ear cytology with treatment based on results. Abdominal radiographs due to doughy abdomen. Reassess dental status in 6 months.</p>
--------------------	---	--	---	---	--	--


<p>2038-1B-309</p>		<p>Adult, male, white Samoyed-type dog</p>	<p>Co-housed in a wood building with indoor/outdoor access. Rubber flaps are at the indoor/outdoor entries. The yard facing the house has a concrete floor, metal roof and metal fencing. The yard facing away from the house has dirt flooring and dug holes with a metal perimeter fence. Interior has dirt flooring and a build-up of feces; one corner of the interior has a low box-like structure with no roof. There is a strong odor of ammonia. There is frozen water available. No food is available.</p>	<p>This dog is thin at a body condition score of 3/9 on the Purina Scale. Grade 2/4 dental disease with moderate dental calculus over most buccal surfaces of teeth. Gingival inflammation present. On the nose there is a 1.5 cm linear area of glossy pigmentation (scar). Shortened tail, approximately 4 coccygeal vertebrae. Moderate fur matting particularly over hind quarters and the back aspect of all legs. Circular area of thinning fur approximately 1 cm in diameter on the right ear tip.</p>	<p>PCV/TS- 43%/8.0. 4DX- negative. Fecal pending.</p>	<p>Vaccinated (Rabies, DAPP, Bordetella), dewormed, started on flea/tick preventative and heartworm preventative. Increase nutritional plane for weight gain, recheck weight in 1 month. Provide grooming. Schedule dental within the next 3 months.</p>
--------------------	---	--	---	--	---	--


<p>2038-1B-310</p>		<p>Adult, female, white Samoyed-type dog</p>	<p>Co-housed in a wood building with indoor/outdoor access. Rubber flaps are at the indoor/outdoor entries. The yard facing the house has a concrete floor, metal roof and metal fencing. The yard facing away from the house has dirt flooring and dug holes with a metal perimeter fence. Interior has dirt flooring and a build-up of feces; one corner of the interior has a low box-like structure with no roof. There is a strong odor of ammonia. There is frozen water available. No food is available.</p>	<p>This dog is thin at a body condition score of 3/9 on the Purina Scale. Grade 2/4 dental disease with heavy calculus over teeth and moderate diffuse gingival inflammation. Left ear has mild waxy debris. Right ear has moderate amount of brown debris. Moderate generalized muscle wasting. Diffuse moderate to severe fur matting throughout the fur coat. Dirt and plant debris in fur coat. Overgrown nails.</p>	<p>PCV/TS- 49%/7.3. 4DX- negative. Witness pregnancy test- negative. CBC/Chem and Fecal pending.</p>	<p>Vaccinated (Rabies, DAPP, Bordetella), dewormed, started on flea/tick preventative and heartworm preventative. Priority for grooming and nail trim. Recommend dental assessment/cleaning in 3-6 months. Treatment for ear debris based on cytology results. Increase nutritional plane for weight gain.</p>
--------------------	---	--	---	--	--	--


<p>2038-1B-311</p>		<p>Adult, female, white Samoyed-type dog</p>	<p>Co-housed in a 3 sided wooden structure with a metal roof. Two walls have open doors that open into a fenced in dirt yard. No food was present. Frozen water was present.</p>	<p>This dog is thin at a body condition score of 3/9 on the Purina Scale. Grade 1/4 dental disease with mild tartar. She has prominent mammary glands. There are mats behind both ears and throughout the body. Large fur mats present on the back of both thighs and on the tail. Dried feces present interdigitally. Overgrown nails.</p>	<p>PCV/TS- 49%/6.9. 4DX-negative. CBC/Chem, Witness pregnancy test and Fecal pending.</p>	<p>Vaccinated (Rabies, DAPP, Bordetella), dewormed, started on flea/tick preventative and heartworm preventative. Recommend nail trim and grooming. Reassess dental status in 6 months. Increase nutritional plane for weight gain.</p>
--------------------	---	--	--	---	---	---


<p>2038-1B-312</p>		<p>Young-adult, female, white Samoyed-type dog</p>	<p>Co-housed in a 3 sided wooden structure with a metal roof. Two walls have open doors that open into a fenced in dirt yard. No food was present. Frozen water was present.</p>	<p>This dog is thin at a body condition score of 3/9 on the Purina Scale. Grade 1/4 dental disease with mild calculus. Small amount of mucopurulent discharge from both nares. Mild generalized muscle wasting. Hair coat is dry, fur on face has large amount of black debris. Multiple small fur mats with plant debris. Right hock has circular area of alopecia with dry skin that is 2 cm in diameter. Overgrown nails.</p>	<p>PCV/TS- 40%/7.8. 4DX- negative. Witness pregnancy test- negative. CBC/Chem, Respiratory PCR and Fecal pending.</p>	<p>Vaccinated (Rabies, DAPP, Bordetella), dewormed, started on flea/tick preventative and heartworm preventative. Provide grooming and nail trim. Improvement of environment is anticipated to resolve region of alopecia over right hock. Recheck nasal discharge and create treatment plan based on findings. Recheck dental status in 6 months. Nutritional management and recheck weight.</p>
--------------------	---	--	--	--	---	---


<p>2038-1B-313</p>		<p>Adult, female, white Samoyed-type dog</p>	<p>Co-housed in a 3 sided wooden structure with a metal roof. Two walls have open doors that open into a fenced in dirt yard. No food was present. Frozen water was present.</p>	<p>This dog is lean at a body condition score of 4/9 on the Purina Scale. Grade 1/4 dental disease with mild gingivitis. Tooth 103 is fractured with tertiary dentin present. Mild matting of tail, hind quarters, and neck. Overgrown nails.</p>	<p>PCV/TS- 48%/7.7. 4DX- negative. Witness pregnancy test-negative. Fecal pending.</p>	<p>Vaccinated (Rabies, DAPP, Bordetella), dewormed, started on flea/tick preventative and heartworm preventative. Reassess dental status and tooth fracture in 6 months. Provide grooming and nail trim.</p>
--------------------	---	--	--	---	--	--


<p>2038-1B-314</p>		<p>Adult, male, white Samoyed-type dog</p>	<p>Co-housed in a 3 sided wooden structure with a metal roof. Two walls have open doors that open into a fenced in dirt yard. No food was present. Frozen water was present.</p>	<p>This dog is very thin at a body condition score of 2/9 on the Purina Scale. Grade 1/4 dental disease with mild tartar. Tail fur is matted with feces. Flea dirt present. Nails are overgrown.</p>	<p>PCV/TS- 47%/7.0. 4DX- negative. CBC/Chem and Fecal negative.</p>	<p>Vaccinated (Rabies, DAPP, Bordetella), dewormed, started on flea/tick preventative and heartworm preventative. Increase nutritional plane for weight gain, recheck weight in 1 month. Provide nail trim and grooming. Reassess dental status in 6 months.</p>
--------------------	---	--	--	--	---	--


<p>2038-1B-315</p>		<p>Adult, male, white Samoyed-type dog</p>	<p>Co-housed in a 3 sided wooden structure with a metal roof. Two walls have open doors that open into a fenced in dirt yard. No food was present. Frozen water was present.</p>	<p>This dog is thin at a body condition score of 3/9 on the Purina Scale. Grade 1/4 dental disease, canine teeth have apical fractures. Both upper lip margins at the level of the maxillary canines are thickened and the left side has a small amount of serosanguinous discharge. Mild pain suspected due to chronic lip irritation. Neuter tattoo present. Mild generalized muscle wasting. Severe fur matting from the top of the head to tail. The tail is so severely matted that it appears as if the dog has two tails. Burrs and fecal debris are present in the fur mats. Fur mats are tight against skin with fecal matting partially occluding anus. Nails are overgrown.</p>	<p>PCV/TS- 49%/7.4. 4DX- negative. CBC/Chem and Fecal Negative.</p>	<p>Vaccinated (Rabies, DAPP, Bordetella), dewormed, started on flea/tick preventative and heartworm preventative. Recommend a high priority grooming and nail trim. Provide dental consultation in the next 3-6 months with radiographs. Increase nutritional plane for weight gain. Clean patient's perianal region and prepuce once daily with Chlorhexidine solution for 5 days. Recommend nsaid for pain associated with lip swelling.</p>
--------------------	---	--	--	--	---	--


<p>2038-1B-316</p>		<p>Adult, male, white Samoyed-type dog</p>	<p>Co-housed in a 3 sided wooden structure with a metal roof. Two walls have open doors that open into a fenced in dirt yard. No food was present. Frozen water was present.</p>	<p>This dog is thin at a body condition score of 3/9 on the Purina Scale. Grade 2/4 dental disease with mild dental calculus and moderate gingival inflammation. Both ears have mild waxy brown debris with no erythema. Mild generalized muscle wasting. Dirty, dry fur coat caked throughout fur coat. Moderate matting of fur around neck, hind quarters, tail which have plant debris,</p>	<p>PCV/TS- 49%/ 8.1. 4DX- negative. CBC/Chem and Fecal negative</p>	<p>Vaccinated (Rabies, DAPP, Bordetella), dewormed, started on flea/tick preventative and heartworm preventative. Provide grooming and nail trim. Increase nutritional plane for weight gain. Recheck dental status within 3-6 months.</p>
--------------------	---	--	--	--	---	--


<p>2038-1B-317</p>		<p>Adult, female, white Samoyed-type dog</p>	<p>Co-housed indoor/outdoor with rubber flaps allowing access to indoor/outdoor run. The run facing the house has concrete flooring with metal fencing and a metal roof. The outdoor run away from the house has dirt flooring and metal fencing. There is a hole under the fence which allows travel between a neighboring dog yard. Access to wooden building with dirt flooring, metal roof, and wooden walls. Strong odor of ammonia within indoor building. Access to frozen water and no food.</p>	<p>This dog is thin at a body condition score of 3/9 on the Purina Scale. Grade 2/4 dental disease with severe calculus and gingivitis. The belly is shaved. Generalized severe fur matting. Nails are overgrown.</p>	<p>PCV/TS- 45%/7.8. 4DX- negative, Witness pregnancy test-negative. CBC/Chem and Fecal negative</p>	<p>Vaccinated (Rabies, DAPP, Bordetella), dewormed, started on flea/tick preventative and heartworm preventative. Reassess dental stage. Provide grooming to remove mats and trim nails. Nutritional management and recheck weight.</p>
--------------------	---	--	--	---	---	---


<p>2038-1B-318</p>		<p>Adult, female, white Samoyed-type dog</p>	<p>Co-housed indoor/outdoor with rubber flaps allowing access to indoor/outdoor run. The run facing the house has concrete flooring with metal fencing and a metal roof. The outdoor run away from the house has dirt flooring and metal fencing. There is a hole under the fence which allows travel between a neighboring dog yard. Access to wooden building with dirt flooring, metal roof, and wooden walls. Strong odor of ammonia within indoor building. Access to frozen water and no food</p>	<p>This dog is a thin at a body condition score of 3/9 on the Purina Scale. Grade 3/4 dental disease with worn incisors and upper canines. Teeth have thick calculus and moderate gingivitis. There are mats behind both ears and the tail is severely matted. Generalized dirty coat. Nails are overgrown.</p>	<p>PCV/TS- 49%/ 7.6. 4DX-negative. CBC/Chem and Fecal - whipworms</p>	<p>Vaccinated (Rabies, DAPP, Bordetella), dewormed, started on flea/tick preventative and heartworm preventative. Provide grooming and nail trim. Recommend dental reassessment. Increase nutritional plane for weight gain, recheck weight in 1 month.</p>
--------------------	---	--	---	---	---	---


<p>2038-1B-319</p>		<p>Adult, female, white Samoyed- type dog</p>	<p>Co-housed indoor/outdoor with rubber flaps allowing access to indoor/outdoor run. The run facing the house has concrete flooring with metal fencing and a metal roof. The outdoor run away from the house has dirt flooring and metal fencing. There is a hole under the fence which allows travel between a neighboring dog yard. Access to wooden building with dirt flooring, metal roof, and wooden walls. Strong odor of ammonia within indoor building. Access to frozen water and no food</p>	<p>This dog is very thin at a body condition score of 2/9 on the Purina Scale. Grade 1/4 dental disease with absent tips of all canine teeth. Tartar present on tooth 108, 202, 104, and 204. Muscle loss secondary to body condition score. Moderate to severe fur matting, with profound fur matting over the top of the lower back, neck, and head. Nails are overgrown.</p>	<p>PCV/TS- 39%/ 8.2. 4DX- negative. Witness pregnancy test- negative. CBC/Chem and Fecal pending.</p>	<p>Vaccinated (Rabies, DAPP, Bordetella), dewormed, started on flea/tick preventative and heartworm preventative. Groom and trim nails. Nutritional management and recheck weight.</p>
--------------------	---	---	---	---	---	--


<p>2038-1B-320</p>		<p>Adult, female, white Samoyed-type dog</p>	<p>Co-housed indoor/outdoor with rubber flaps allowing access to indoor/outdoor run. The run facing the house has concrete flooring with metal fencing and a metal roof. The outdoor run away from the house has dirt flooring and metal fencing. There is a hole under the fence which allows travel between a neighboring dog yard. Access to wooden building with dirt flooring, metal roof, and wooden walls. Strong odor of ammonia within indoor building. Access to frozen water and no food.</p>	<p>This dog is of ideal body condition at a score of 5/9 on the Purina scale. Grade 2/4 dental disease with wear on incisors and upper canines, and moderate tartar. The eyelid of the left eye has a 1 mm in diameter round mass with small crusting and mild discharge. She has prominent mammary glands with thin red discharge. Flea dirt is present. Few mild hair mats diffusely. The left flank has extensive alopecia. Right rear digit 5 has a broken nail with active hemorrhage and mildly painful. Overgrown nails.</p>	<p>PCV/TS- 47%/7.1. 4DX- negative. Witness pregnancy test- negative. CBC/Chem pending. Fecal negative. Aural cytology-negative.</p>	<p>Vaccinated (Rabies, DAPP, Bordetella), dewormed, started on flea/tick preventative and heartworm preventative. Provide grooming and nail trim. Remove broken nail and provide bandage. Recommend nsaid for 7 days due to pain associated with broken toe nail and oral antibiotic for 7 days due to broken toenail.</p>
--------------------	---	--	--	---	---	--


<p>2038-1B-321</p>		<p>Adult, male, white Samoyed-type dog</p>	<p>Co-housed indoor/outdoor with rubber flaps allowing access to indoor/outdoor run. The run facing the house has concrete flooring with metal fencing and a metal roof. The outdoor run away from the house has dirt flooring and metal fencing. There is a hole under the fence which allows travel between a neighboring dog yard. Access to wooden building with dirt flooring, metal roof, and wooden walls. Strong odor of ammonia within indoor building. Access to frozen water and no food.</p>	<p>This dog is thin at a body condition score of 3/9 on the Purina scale. Grade 3/4 dental disease with moderate tartar, wear to lower incisors and attrition of lower left canine tooth. Both ears have mild brown debris. Flea dirt present (flea feces), no live fleas observed. Severe matting of fur with debris on body and legs. Fur matting behind ears and on tail. Large mat under black nylon collar. Dried fecal material around anus (perianal area). Overgrown nails.</p>	<p>PCV/TS- 41%/7.9, 4DX-negative, Ear cytology-negative, Chemistry globulin 4.0 g/dL (1.6-3.6 g/dL), CBC: eosinophils 2,340 /uL (0-1200 uL). Fecal pending.</p>	<p>Vaccinated (Rabies, DAPP, Bordetella), dewormed, started on flea/tick preventative and heartworm preventative. Groom and nail trim. Nutritional management. Ear treatment based on diagnostic results. Recommend dental consultation and cleaning</p>
--------------------	---	--	--	---	---	--


<p>2038-1B-322</p>		<p>Adult, female, white Samoyed-type dog</p>	<p>Co-housed indoor/outdoor with rubber flaps allowing access to indoor/outdoor run. The run facing the house has concrete flooring with metal fencing and a metal roof. The outdoor run away from the house has dirt flooring and metal fencing. There is a hole under the fence which allows travel between a neighboring dog yard. Access to wooden building with dirt flooring, metal roof, and wooden walls. Strong odor of ammonia within indoor building. Access to frozen water and no food.</p>	<p>This dog is thin at a body condition score of 3/9 on the Purina scale. Grade 3/4 dental disease with heavy tartar and wear to distal surfaces of upper canine teeth. Prominent mammary glands and evidence of previous litters. Dirty hair coat. Small mats behind ears and on tail. Overgrown nails.</p>	<p>PCV/TS- 41%/ 7.7, 4DX- negative, Witness pregnancy test- positive, Chemistry: Globulin 4.0 g/dL (1.6-3.6 g/dL). CBC: Platelets 546 x10³ /uL (170-400 uL), Eosinophils 1,974 /uL (0-1,200 /uL)and Fecal pending.</p>	<p>Vaccinated (Rabies, DAPP, Bordetella), dewormed, started on flea/tick preventative and heartworm preventative. Nail trim and groom. Nutritional management and monitor weight monthly. Recommend dental cleaning.</p>
--------------------	---	--	--	--	---	--


<p>2038-1B-323</p>		<p>Adult, female, white Samoyed-type dog</p>	<p>Co-housed indoor/outdoor with rubber flaps allowing access to indoor/outdoor run. The run facing the house has concrete flooring with metal fencing and a metal roof. The outdoor run away from the house has dirt flooring and metal fencing. There is a hole under the fence which allows travel between a neighboring dog yard. Access to wooden building with dirt flooring, metal roof, and wooden walls. Strong odor of ammonia within indoor building. Access to frozen water and no food.</p>	<p>This dog is lean at a body condition score of 4/9 on the Purina scale. Grade 2/4 dental disease with moderate calculus accumulation. Around both eyes is stained fur consistent with epiphora. In both ears, there is mild amount of waxy debris. Development of mammary chain and evidence of previous litters. Irregularly shaped ("V to L") area of alopecia on left dorsal lateral lumbar region measuring approximately 13x15cm in diameter, no dermatitis present - consistent with a previous wound. Dirty hair coat, mild amount of soft feces on anus, minimal fur matting and moderately overgrown nails.</p>	<p>PCV/TS- 41%/ 8.1. 4DX- negative. Witness pregnancy test-negative. Fecal - negative.</p>	<p>Vaccinated (Rabies, DAPP, Bordetella), dewormed, started on flea/tick preventative and heartworm preventative. Recommend ophthalmic consult. Reevaluate need for dental prophylaxis in 3-6 months. Recommend bath, brush out and nail trim.</p>
--------------------	---	--	--	--	--	--


<p>2038-1B-324</p>		<p>Adult, female, white Samoyed-type dog</p>	<p>Co-housed in a wood building with indoor/outdoor access. Rubber flaps are at the indoor/outdoor entries. The yard facing the house has a concrete floor, metal roof and metal fencing. The yard facing away from the house has dirt flooring and dug holes with a metal perimeter fence. A mature tree is down in the neighboring yard altering the integrity of a fence separating another dog yard. Interior has dirt flooring and a build-up of feces; one corner of the interior has a low box-like structure with no roof. There is a strong odor of ammonia. A bucket has scant frozen water. No food is available.</p>	<p>This dog is thin at a body condition score of 3/9 on the Purina Scale. Grade 1/4 dental disease with worn teeth. Mild grade 1-2 heart murmur. Dirty skin along the underside of body, hair coat has minimal matting. Developed mammary glands suggestive of previous litters.</p>	<p>PCV/TS- 41%/ 7.2, 4DX- negative, Witness pregnancy test- negative , CBC/Chem - pending. Fecal negative.</p>	<p>Vaccinated (Rabies, DAPP, Bordetella), dewormed, started on flea/tick preventative and heartworm preventative. Repeat cardiac auscultation within a week to reassess murmur. Nutritional management and recheck weight.</p>
--------------------	---	--	--	--	--	--


<p>2038-1B-325</p>		<p>Adult, male, white Samoyed- type dog</p>	<p>Co-housed in a wood building with indoor/outdoor access. Rubber flaps are at the indoor/outdoor entries. The yard facing the house has a concrete floor, metal roof and metal fencing. The yard facing away from the house has dirt flooring and dug holes with a metal perimeter fence. Interior has dirt flooring and a build-up of feces; one corner of the interior has a low box-like structure with no roof. There is a strong odor of ammonia. There is frozen water available. No food is available.</p>	<p>This dog is lean at a body condition score of 4/9 on the Purina scale. Grade 3/4 dental disease with possible pulp exposure of upper left canine tooth, heavy tartar and wear to canine teeth. Both eyes have mild clear discharge. Severe matting with dried organic debris on back aspect of both front legs, under the belly and the hind legs. Mats behind ears. Fecal material dried into the fur around the anus and between paw pads. Flea dirt present (flea feces), no live fleas noted. Nails overgrown. Suspect pain/discomfort due to matting.</p>	<p>PCV/TS- 43%/7.2. 4DX-Negative. CBC/Chem pending. Fecal pending.</p>	<p>Vaccinated (Rabies, DAPP, Bordetella), dewormed, started on flea/tick preventative and heartworm preventative. Priority for grooming and nail trim. Recommend dental assessment/cleaning.</p>
--------------------	---	---	---	---	--	--


<p>2038-1C-001</p>		<p>Adult, female, white Samoyed-type dog</p>	<p>Co-housed with indoor/outdoor access. Indoor was a 3 sided wooden structure with a metal roof. Two walls have open doors that open into a fenced in dirt yard. No food was present. Frozen water was present.</p>	<p>This dog is at a lean body condition score of 4/9 on the Purina Scale. Grade 2/4 dental disease with worn enamel on tooth 104 and 204. Mild calculus accumulation and dental inflammation present. Dirty fur coat with dirt and debris diffusely distributed into moderate fur matting particularly around the neck, hind quarters and tail</p>	<p>PCV/TS- 51%/ 7.7. 4DX- negative. Witness pregnancy test- negative. CBC/Chem and Fecal pending.</p>	<p>Vaccinated (Rabies, DAPP, Bordetella), dewormed, started on flea/tick preventative and heartworm preventative. Recommend moderate priority for grooming. Reassess dental status in 3-6 months.</p>
--------------------	---	--	--	--	---	---


<p>2038-1C-002</p>		<p>Adult, male, white Samoyed-type dog</p>	<p>Co-housed with indoor/outdoor access. Indoor was a 3 sided wooden structure with a metal roof. Two walls have open doors that open into a fenced in dirt yard. No food was present. Frozen water was present.</p>	<p>This dog is at a very thin body condition score of 2/9 on the Purina Scale. Grade 2/4 dental disease with mild tartar on 108 and 208, wear on the back of 204 a and 104, with generalized moderate gingivitis. The right testicle is severely atrophied and 50% smaller than the left testicle. There are large mats in front of the left ear that extends around the neck and behind the right ear. There are erosions of the skin near the right ear secondary to the fur mats. Moderate to severe fur mats on the underside of the chest. The tail and rectal region have severe fur matting composed of feces and debris.</p>	<p>PCV/TS- 48%/ 7.9. 4DX-negative. CBC/Chem and Fecal pending.</p>	<p>Vaccinated (Rabies, DAPP, Bordetella), dewormed, started on flea/tick preventative and heartworm preventative. Increase nutritional plane for weight gain, recheck weight in 1 month. Shave all mats. Schedule priority neuter and submit the right testicle for biopsy. Recommend to recheck dental status in 2 months for scheduling of dental cleaning.</p>
--------------------	---	--	--	--	--	---


<p>2038-1C-003</p>		<p>Young-adult, female, white Samoyed-type dog</p>	<p>Co-housed with indoor/outdoor access. Indoor was a 3 sided wooden structure with a metal roof. Two walls have open doors that open into a fenced in dirt yard. No food was present. Frozen water was present.</p>	<p>This dog is at thin body condition score of 3/9 on the Purina Scale. Grade 1 dental disease with very mild calculus noted. There is brown-to-red vaginal discharge that is slightly malodorous. Mild generalized muscle wasting. Dirty, dry hair coat with mild fur matting of hind quarters and tail. Small amount of alopecia of both ear tips. Overgrown nails.</p>	<p>PCV/TS- 48%/ 7.4. 4DX- negative. Witness pregnancy test- negative. CBC/Chem and Fecal pending.</p>	<p>Vaccinated (Rabies, DAPP, Bordetella), dewormed, started on flea/tick preventative and heartworm preventative. Recommend brushing to remove mild mats and provide a bath and nail trim. Increase nutritional plane for weight gain, recheck weight in 1 month. Monitor vaginal discharge and repeat temperature checks. Recommend behavior consult and starting anxiolytic medication.</p>
--------------------	---	--	--	---	---	---


<p>2038-1C-004</p>		<p>Adult, male, white Samoyed- type dog</p>	<p>Co-housed with indoor/outdoor access. Indoor was a 3 sided wooden structure with a metal roof. Two walls have open doors that open into a fenced in dirt yard. No food was present. Frozen water was present.</p>	<p>This dog is at very thin body condition score of 2/9 on the Purina Scale. He required sedation for examination. Grade 1/4 dental disease with mild tartar on tooth 108 and 208. He has moderate to severe dirty fur matting along the head, neck, underside of body, and region of the anus.</p>	<p>PCV/TS- 38%/ 6.8, 4DX- negative, Witness pregnancy test- , CBC/Chem and Fecal pending.</p>	<p>Vaccinated (Rabies, DAPP, Bordetella), dewormed, started on flea/tick preventative and heartworm preventative. Recommend to recheck dental grade in 1 year. Recommend to have a full body shave and bath. Increase nutritional plane for weight gain, recheck weight in 1 month.</p>
--------------------	---	---	--	---	---	---


<p>2038-1C-005</p>		<p>Adult, female, white Samoyed-type dog</p>	<p>Co-housed with indoor/outdoor access. The standing shed had a metal roof, one of the walls 4 had a hole in it. Indoor shed had cement flooring with an elevated wooden platform, nails exposed from dilapidated wooden platform. A bucket is present with scant frozen water. A drainage pipe empties into yard resulting in a pool of water in a dirt hole.</p>	<p>This dog is lean at a body condition score of 4/9 on the Purina Scale. She has grade 2/4 dental disease with generalized moderate tartar and wear to the lower incisors and the upper canines. Mild debris and reddening of both ears. The tip of the right ear has a 2 cm area of alopecia. There are large fur mats behind her ears, along her rump, along her tail, and under her collar. The fur mats have plant debris within them. The fur coat has an ammonia odor to it. Nails are overgrown.</p>	<p>PCV/TS- 41%/7.0, 4DX- negative. Witness pregnancy test- negative. CBC/Chem and Fecal pending.</p>	<p>Vaccinated (Rabies, DAPP, Bordetella), dewormed, started on flea/tick preventative and heartworm preventative. Recheck dental status in 6 months. Recommend an ear cytology with treatment based on results. Patient should be groomed and have a nail trim.</p>
--------------------	---	--	---	--	--	---


<p>2038-1C-007</p>		<p>Adult, male, white Samoyed-type dog</p>	<p>Co-housed with indoor/outdoor access. The standing shed had a metal roof, one of the walls 4 had a hole in it. Indoor shed had cement flooring with an elevated wooden platform, nails exposed from dilapidated wooden platform. A bucket is present with scant frozen water. A drainage pipe empties into yard resulting in a pool of water in a dirt hole.</p>	<p>This dog is lean at a body condition score of 4/9 on the Purina Scale. He has grade 2/4 dental disease with moderate tartar on teeth. There is mild clear discharge from both eyes. Both ears have brown discharge and the tips of both ears have absent fur with crusting of the skin. There is severe fur matting behind the ears, on the body, the tail, and the rump which have dried feces and debris. The region around the anus was shaved revealing reddened skin. There is a smell of ammonia to the fur coat. Hair mats encircle the collar. The nails are overgrown.</p>	<p>PCV/TS- 41%/ 8.0, 4DX- negative, Ear cytology - unremarkable. CBC/Chem and Fecal pending.</p>	<p>Vaccinated (Rabies, DAPP, Bordetella), dewormed, started on flea/tick preventative and heartworm preventative. Recommend to provide a priority groom due to discomfort associated with hair mats. Provide nail trim. Clean ears to remove debris. Recheck skin around anus in 1 week.</p>
--------------------	---	--	---	--	--	--


<p>2038-1C-008</p>		<p>Geriatric, male, white Samoyed-type dog</p>	<p>Co-housed within the private residence. Strong ammonia odor throughout the first floor. The dog inhabited the first floor. The flooring had both new and old dog urine and feces present. A bowl with dry dog kibble was present. A metal bowl was partially filled with water, tissue paper was present in water bowl. A bowl with dog kibble was present.</p>	<p>This dog is emaciated at a body condition score of 1/9 on the Purina Scale. He is approximately 5% dehydrated with pale pink mucus membranes, and a depressed mentation. He has grade 3/4 dental disease with diffuse gingival hypertrophy and moderate wear of incisors. Heart sounds are muffled on both sides of his chest. Both of his eyes are cloudy and have dried greenish-yellow discharge. The ears have moderate to heavy waxy debris, he is painful on examination of both ears. The right testicle is approximately twice as large as the left. There is severe generalized muscle wasting. Both of his knees have crepitus and severe decreased range of motion. The fur coat is severely diffusely matted with thinning of fur over bony prominences. The patient is unable to walk and has mildly overgrown nails.</p>	<p>Necropsy pending, CBC/Chem and Fecal pending.</p>	<p>Humanely euthanized</p>
--------------------	---	--	--	---	--	----------------------------


<p>2038-1C-009</p>		<p>Adult, female, white Samoyed-type dog</p>	<p>Co-housed within the private residence. Strong ammonia odor throughout the first floor. The dog inhabited the first floor. The flooring had both new and old dog urine and feces present. A bowl with dry dog kibble was present. A metal bowl was partially filled with water, tissue paper was present in water bowl. A bowl with dog kibble was present.</p>	<p>This dog is lean at a body condition score of 4/9 on the Purina scale. Grade 4/4 (severe) dental disease with several teeth having extreme gingival recession, pus (purulent) debris at the gum line, red inflamed gums, loose multi-rooted teeth and painful upon manipulation. Both eyes have mild clear discharge. Both ears have moderate amount of brown waxy, especially close to the ear drum (tympanic membrane) on right side with sensitivity present. Excessive layers of flaking skin buildup in hair coat, moderate matting of undercoat. Nails moderately overgrown. Presence of multi-lobulated mass 2x3cm in diameter associated with mid left mammary chain.</p>	<p>PCV/TS- 51%/ 7.1. 4DX- negative. Witness pregnancy test- negative. Ear cytology- pending. CBC/Chem pending. Fecal negative.</p>	<p>Vaccinated (Rabies, DAPP, Bordetella), dewormed, started on flea/tick preventative and heartworm preventative. Recommend dental + extractions in one week. Prescribe pain medication until dental. Monitor food intake due to oral pain. Provide wet and dry food or soaked dry food. Recommend grooming at time of dental. Recommend ear treatment based upon cytology results. Recommend excisional biopsy of mass and histopathology.</p>
--------------------	---	--	--	--	--	---


<p>2038-1C-010</p>		<p>Adult, female, white Samoyed-type dog</p>	<p>Co-housed within the private residence. Strong ammonia odor throughout the first floor. The dog inhabited the first floor. The flooring had both new and old dog urine and feces present. A bowl with dry dog kibble was present. A metal bowl was partially filled with water, tissue paper was present in water bowl. A bowl with dog kibble was present.</p>	<p>This dog is of ideal body condition at a score of 5/9 on the Purina Scale. Grade 2/4 dental disease with significant gingival recession at the first left upper incisor. Very mild episcleral injection; subjectively mild lateral strabismus bilaterally. Both ears have moderate dry waxy debris with minimal redness. Abdominal scar present (rule out spay or previous C-Section). Severely matted throughout head, neck, trunk; fecal mats present at tail and around the anus; mats encompassing the entirety of hind quarters, tail is encased in one mat; dry and dirty coat. Nails moderately overgrown.</p>	<p>PCV/TS- 49%/7.2. 4DX- Negative. Witness pregnancy test-negative. Ear cytology pending. Unremarkable CBC/Chemistry. Fecal pending.</p>	<p>Vaccinated (Rabies, DAPP, Bordetella), dewormed, started on flea/tick preventative and heartworm preventative. Recommend dental prophylaxis within next couple months, dental radiographs +/- extraction. Priority for grooming, nail trim. Recommend ophthalmic consult.</p>
--------------------	---	--	--	--	--	--

<p>2038-1C-011</p>		<p>Senior, female, white Samoyed-type dog</p>	<p>Co-housed within the private residence. Strong ammonia odor throughout the first floor. The dog inhabited the first floor. The flooring had both new and old dog urine and feces present. A bowl with dry dog kibble was present. A metal bowl was partially filled with water, tissue paper was present in water bowl. A bowl with dog kibble was present.</p>	<p>This dog is overweight at a body condition score of 6/9 on the Purina Scale. Mild degenerative muscle wasting. Bilateral tearing and clouding consistent with lenticular sclerosis. Both ears have moderate dark brown waxy debris bilaterally with mild redness. Grade 3/4 dental disease with gingival hypertrophy, redness, moderate-severe calculus and discomfort upon manipulation of mouth. Loss of pigment on nose. Diffuse build-up of scaling skin and debris in hair coat including burrs and plant material; undercoat is one mat, largest mat present is on tail that contains too numerous to count plant seeds/burrs, fecal matting on tail and perivulvar area; discoloration on all four feet consistent with salivary staining. On the left side of the chest is an area of matting with dark brown-red crusts. Moderately overgrown nails. Mild-moderately painful due to potential arthritis and matting.</p>	<p>PCV/TS- 43%/8.7. 4DX-Negative. Witness pregnancy test-negative. Chemistry: TP 7.9 g/dL (5-7.4 g/dL), Globulin 4.6 g/dL (1.6-3.6 g/dL). CBC and T4 is unremarkable. U/A, Ear cytology and Fecal pending.</p>	<p>Vaccinated (Rabies, DAPP, Bordetella), dewormed, started on flea/tick preventative and heartworm preventative. Recommend ophthalmic consult dental prophylaxis within next week due to pain. Monitor food intake (if eating due to oral pain) and administration of pain meds until dental prophylaxis. Feed a combination of wet and dry or soften dry food until dental. Recommend excisional biopsy and evaluation of multi-lobulated area on left thorax. Recommend first-line antibiotics, scrubbing with dilute chlorhexidine twice daily followed by dressing to prevent contamination from shavings. Recommended ear cleaning followed by appropriate treatment based upon results. Priority grooming and nail trim.</p>
--------------------	---	---	--	--	--	---

<p>2038-1C-012</p>		<p>Senior, female, dilute calico domestic short haired cat</p>	<p>Co-housed within the private residence. Strong ammonia odor present throughout the house. The cat had access to the first floor and basement. On the first floor and in the basement, there were overflowing cat litter boxes with a significant amount of urine and feces within them. On the flooring of the first floor, there was urine and feces (both old and new) present. A metal bowl partially filled with water, tissue paper present in water bowl.</p>	<p>This cat is thin at a body condition score of 3/9 on the Purina Scale. Grade 2/4 dental disease with teeth 304, 105, 205, 301, 302, and 305 absent and tooth 104 fractured. There is mild gingivitis and tarter on the remaining teeth. Both eyes have mild mucoid discharge around the medial canthus. Both ears have moderate debris and are very itchy (pruritic). Both front legs have mild alopecia consistent with over grooming. There is a lesion measuring 1.5 cm on dorsal cervical area and erosive lesion on the right side of the neck consistent with the pruritic ears. A suspected spay scar is observed. The nails are overgrown.</p>	<p>PCV/TS- 40%/ 8.8. FeLV/FIV - negative. Fecal pending. CBC/Chem/T4 pending. Fungal culture pending. Ear cytology pending.</p>	<p>Vaccinated (Rabies, DAPP, Bordetella), dewormed, started on flea/tick preventative and heartworm preventative. CBC/Chemistry/T4 pending, provide adequate diet and nutrition. Pending results of cytology clean and treat both ears. Provide a dental consultation and dental cleaning. Based on fungal culture, provide treatment for the neck lesions. Trim nails.</p>
--------------------	---	--	--	---	---	---

<p>2038-1C-013</p>		<p>Senior, female, calico domestic medium haired cat</p>	<p>Co-housed within the private residence. Strong ammonia odor present throughout the house. The cat had access to the first floor and basement. On the first floor and in the basement, there were overflowing cat litter boxes with a significant amount of urine and feces within them. On the flooring of the first floor, there was urine and feces (both old and new) present. A metal bowl partially filled with water, tissue paper present in water bowl.</p>	<p>This cat is very thin at a body condition score of 2/9 on the Purina Scale. Grade 1/4 dental disease with teeth 105 and 205 present, 405 and 305 absent and moderate tartar and gingivitis on tooth 207. Nuclear sclerosis consistent with geriatric age and dry and wet serous ophthalmic discharge. Brown otic debris obscuring the right tympanic membrane. Referred noise heard in upper airway consistent with possible URI. Right kidney palpates smaller than the left. A suspected spay scar observed. Multiple mats in fur over left and right lumbosacral area. Multiple mats noted starting over lateral lumbosacral coalescing over right thigh. Scabs noted over dorsal cranial. Nails overgrown.</p>	<p>PCV/TS- 40%/8.1. FeLV/FIV - negative. Fecal pending. Ear cytology, CBC/Chem/T4 pending.</p>	<p>Vaccinated (Rabies, DAPP, Bordetella), dewormed, started on flea/tick preventative and heartworm preventative. CBC/Chem/T4 pending before treatment of discharge and/or respiratory noise. Reweigh in 1 month with adequate diet and nutrition and pending blood work. Recheck dental in 6 months. Clip or cut mats. Cytology pending, clean and treat. Trim nails.</p>
--------------------	---	--	--	---	--	--

<p>2038-1C-014</p>		<p>Senior, female, white domestic short haired cat</p>	<p>Co-housed within the private residence. Strong ammonia odor present throughout the house. The cat had access to the first floor and basement. On the first floor and in the basement, there were overflowing cat litter boxes with a significant amount of urine and feces within them. On the flooring of the first floor, there was urine and feces (both old and new) present. A metal bowl partially filled with water, tissue paper present in water bowl.</p>	<p>This cat is at a lean body condition score of a 4/9 on the Purina Scale. Both eyes have discharge. Both ears have dirt and debris. A suspected spay scar is observed. The nails are overgrown.</p>	<p>PCV/TS- 31%/8.6. FeLV/FIV - negative. Ear cytology/CBC/Chem/T4 pending. Fecal pending. Fluorescein stain negative</p>	<p>Vaccinated (Rabies, DAPP, Bordetella), dewormed, started on flea/tick preventative and heartworm preventative. Fluorescein staining results are pending for both eyes, treatment plan will be created based on results. Ear cytology results are pending, clean ears, a treatment plan will be created based on results. Trim nails.</p>
--------------------	---	--	--	---	--	---

<p>2038-1C-015</p>		<p>Senior, female, white and brown tabby domestic short haired cat</p>	<p>Co-housed within the private residence. Strong ammonia odor present throughout the house. The cat had access to the first floor and basement. On the first floor and in the basement, there were overflowing cat litter boxes with a significant amount of urine and feces within them. On the flooring of the first floor, there was urine and feces (both old and new) present. A metal bowl partially filled with water, tissue paper present in water bowl.</p>	<p>This cat is at a overweight body condition score of a 6/9 on the Purina Scale. Her eyes have nuclear sclerosis consistent with geriatric aging. Both of her ears have dry granular tan debris, the debris is obstructing the visibility of both ear drums. There is tarter on tooth 104,107, and 207. Tooth 205, 405, and 201 are absent. The nails are overgrown. A suspected spay scar is observed.</p>	<p>PCV/TS- 41%/ 8.6. FeLV/FIV - negative. CBC/Chem/T4, ear cytology, and fecal pending.</p>	<p>Vaccinated (Rabies, DAPP, Bordetella), dewormed, started on flea/tick preventative and heartworm preventative. Recheck dental status in 6 months. Ear cytology results are pending, clean ears, a treatment plan will be created based on results. Trim nails.</p>
--------------------	---	--	--	--	---	---