



SOUTHWESTERN  
INSTITUTE OF FORENSIC SCIENCES  
AT DALLAS



Office of the Medical Examiner  
In the County of Dallas  
State of Texas

This affidavit is in compliance with Texas Rules of Criminal Evidence, Rule 902(10b).

Case No. IFS-15-08020 in the matter of

**Russell, Charles Wayne, deceased.**

Before me, the undersigned authority, personally appeared Rebecca Beshay, who being duly sworn, deposed as follows:

My name is Rebecca Beshay. I am over 21 years of age, of sound mind, capable of making this affidavit, and personally acquainted with the facts herein stated:

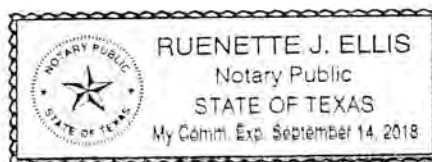
I am the Deputy Custodian of Records of the Dallas County Medical Examiner's Office. Attached hereto are 8 pages of records and xx photographs from the Dallas County Medical Examiner's Office. These said 8 pages of records and xx photographs are kept by the Dallas County Medical Examiner's Office in the regular course of business, and it was the regular course of business of the Dallas County Medical Examiner's Office for an employee or representative, or a doctor permitted to practice in the Dallas County Medical Examiner's Office, with personal knowledge of the act, event, condition, opinion or diagnosis, recorded to make the record or to transmit information thereof to be included in such record; and the record was made at or near the time or reasonably soon thereafter. The records attached hereto are the original or exact duplicates of the original.

*Rebecca Beshay*

SWORN TO AND SUBSCRIBED before me on July 29, 2015

*Ruennette J. Ellis*

Notary Public in and for Dallas County, Texas  
My commission expires



(By statute, the original records are retained by the Dallas County Medical Examiner's Office. See Art. 49.25, Sec. 11, Vernons Texas Statutes, CCP.)



SOUTHWESTERN  
INSTITUTE OF FORENSIC SCIENCES  
AT DALLAS



Office of the Medical Examiner  
Autopsy Report

COPY  
DALLAS COUNTY  
INSTITUTE OF FORENSIC SCIENCES

Case: IFS-15-08020 - CC

Decedent: Russell, Charles Wayne 46 years White Male DOB: 06/03/1968

Date of Death: 05/17/2015 (Actual)

Time of Death: 01:30 PM (Actual)

Examination Performed: 05/18/2015 08:00 AM

Body Weight: 190 lbs BMI: 25.77

Body Length: 72 in

**ORGAN WEIGHTS:**

Brain: 1,540 g	Right Lung: 600 g	Right Kidney: 190 g
Heart: 450 g	Left Lung: 540 g	Left Kidney: 190 g
Liver: 1,670 g	Spleen: 70 g	

This autopsy is performed at the request of W.H. Peterson, Justice of the Peace, Precinct 1, Place 2, McLennan County, Texas.

**EXTERNAL EXAMINATION**

The body is photographed, fingerprinted, palmprinted, x-rayed and tagged. When first viewed, the hands are bagged.

The body is received dressed in a black leather vest, a black T-shirt, jeans, white briefs, socks, and boots. A knotted segment of leather on a hook is attached to a belt loop. Two lighters, a tube of Carmex lip balm, a raffle ticket, a broken wooden nickel, three \$1 bills, twelve quarters, eight dimes, five nickels, and fifteen pennies are received with the body. The pockets contain a ziplock baggie full of a green leafy material and an additional small ziplock baggie containing a metallic disc. The clothing and ziplock baggies are retained. The other items are released.

Gunshot defects are within the T-shirt and vest. A medium caliber, minimally deformed, copper jacketed, spent bullet is recovered from a defect in the back of the vest. The base of the bullet is inscribed "15-08020" over "JU". The bullet is photographed, sealed in an appropriately labeled envelope and submitted to the Criminal Investigation Laboratory.

The body is that of a well-developed, well-nourished white man whose appearance is compatible with the stated age of 46 years. The body weighs 190 pounds and is 72 inches long. The body is cool, rigor is fully developed, and the posterior lividity is fixed. The body is well-preserved and is not embalmed.



The scalp is shaved. The irides are blue, and there are no petechiae of the bulbar or palpebral surfaces of the conjunctivae. There is no beard or mustache. The ears, nose and lips are unremarkable. The teeth are natural and in good condition. The chest and breasts are symmetrical. The abdomen is flat. The external genitalia, anus and perineum are unremarkable. The penis is circumcised and the testicles are descended into the scrotum. The extremities are well-developed and symmetrical.

#### EVIDENCE OF THERAPY

None.

#### IDENTIFYING MARKS AND SCARS

Numerous tattoos are on the scalp, neck, chest, right flank, back, right and left arms, right and left forearms, right and left hands, and distal anterior right thigh.

#### EVIDENCE OF INJURY

Gunshot wound of chest:

There is a gunshot wound of entrance of the right side of the chest, located 13 inches below the top of the head and 1 inch to the right of the anterior midline of the chest. The entrance wound is circular, measures 1/4 inch in diameter, and is surrounded by a circumferential 1/16 inch marginal abrasion. There is no soot or stippling.

After perforating the skin and subcutaneous tissue, the bullet sequentially perforates the sternum, the pericardial sac, the right auricle of the heart, the root of the aorta, the lower lobe of the right lung, the thoracic aorta, the body of the eighth thoracic vertebra, and the head of the right ninth rib.

There is a gunshot wound of exit of the right side of the back, located 19-1/2 inches below the top of the head and 1-3/4 inch to the right of the posterior midline. The entrance wound is ovoid, slightly irregular, measures 1/2 inch, and is surrounded by a circumferential, up to 1/4 inch, shored abrasion. There is no firearm residue.

Associated with this wound, the wound track is hemorrhagic and pulped. The right pleural cavity contains 200 mL of liquid blood and the pericardial sac contains 150 mL of liquid blood. Mediastinal soft tissue hemorrhage is dense.

The directions of the bullet are from front to back and downward, with no significant left or right deviation.

Blunt force injuries:

The left side of the scalp has a stellate, full-thickness laceration which extends to the galea. The laceration measures 2 inches in maximum dimension. It is centered 2 inches below the top of the head and 3-1/4 inch superior to and 1/2 inch anterior to the superior attachment of the pinna of the left ear. There is tissue bridging within the depths of the wound. Reflection of the scalp reveals corresponding subscalpular and subgaleal hemorrhage.





Russell, Charles Wayne

DALLAS COUNTY  
INSTITUTE OF FORENSIC SCIENCES

The posterior scalp has a 1-1/2 inch linear, obliquely oriented, full-thickness laceration which extends to the galea. The margins are abraded and tissue bridging is within the depths of the wound. It is located 5-1/2 inches below the top of the head and 1 inch to the left of the posterior midline. By internal examination, there is associated subscalpular and subgaleal hemorrhage.

The right side of the head has a 1-1/2 inch contusion with a horizontal, linear 1-1/4 inch abrasion on the superior edge and an obliquely oriented 1 inch linear abrasion on the inferior edge. It is located 2-1/2 inches below the top of the head and 2-3/4 inches superior to and 1 inch anterior to the superior attachment of the pinna of the right ear. Reflection of the scalp reveals corresponding subscalpular and subgaleal hemorrhage.

The undersurface of the chin has a 1 inch diameter abrasion. The right buttock has a 1/4 inch abrasion. The posterior left elbow has a 1/2 inch diameter crusted abrasion. The anterior right knee has a 1-1/4 inch abrasion. Crusted up to 1/4 inch abrasions are scattered over the anterior left leg.

#### INTERNAL EXAMINATION

**BODY CAVITIES:** See previous description. The thoracic and abdominal organs are in their normal anatomic positions. The left pleural cavity and peritoneal cavity contain no fluid. There are no adhesions.

**HEAD:** See previous description. The skull is free of fractures. There is scant hemorrhage within the petrous ridges bilaterally. The dura and dural sinuses are unremarkable. There are no epidural, subdural or subarachnoid hemorrhages. The leptomeninges are thin and delicate. The cerebral hemispheres are symmetrical, with an unremarkable gyral pattern. The cranial nerves and blood vessels are unremarkable. Sections through the cerebral hemispheres, brainstem, and cerebellum are unremarkable. There are no hemorrhages in the deep white matter or the basal ganglia. The cerebral ventricles contain no blood. The spinal cord, as viewed from the cranial cavity, is unremarkable.

**NECK:** The soft tissues and prevertebral fascia are unremarkable. The hyoid bone and laryngeal cartilages are intact. The lumen of the larynx is not obstructed.

**CARDIOVASCULAR SYSTEM:** See previous description. The intimal surface of the abdominal aorta is involved by mild atherosclerosis. The aorta and its major branches and the great veins are normally distributed. The pulmonary arteries contain no thromboemboli. The pericardium, epicardium, and endocardium are smooth and glistening. There are no thrombi in the atria or ventricles. The foramen ovale is closed. The coronary arterial system is free of significant atherosclerosis. The atrial and ventricular septa are intact. The cardiac valves are unremarkable. The myocardium is dark red-brown and firm.

**RESPIRATORY SYSTEM:** See previous description. The upper airway is not obstructed. The laryngeal mucosa is smooth and unremarkable, without petechiae. The pleural surfaces are smooth and glistening. Scant white foam is within the major bronchi which are otherwise unremarkable. Sectioning of the lungs discloses a dark red-blue, moderately congested parenchyma.

**HEPATOBIILIARY SYSTEM:** The liver is covered by a smooth, glistening capsule. The parenchyma is dark red-brown and moderately congested. The gallbladder contains approximately 10 mL of dark green bile, with no calculi.

**GASTROINTESTINAL SYSTEM:** The esophageal mucosa is gray, smooth, and unremarkable. The stomach contains



Case: IFS-15-08020 - CC

Russell, Charles Wayne

approximately 100 mL of green liquid and partially digested food. There are no tablets or capsules. The gastric mucosa has normal rugal folds, and there are no ulcers. The small and large intestines are externally unremarkable. The appendix is present. The pancreas is unremarkable externally and upon sectioning.

**GENITOURINARY SYSTEM:** The capsules of both kidneys strip with ease to reveal smooth and slightly lobulated surfaces. The cortices are of normal thickness, with well-demarcated corticomedullary junctions. The calyces, pelves, and ureters are unremarkable. The urinary bladder contains approximately 20 mL of clear yellow urine. The mucosa is gray, smooth, and unremarkable. The prostate gland is unremarkable externally and upon sectioning.

**ENDOCRINE SYSTEM:** The thyroid and adrenal glands are unremarkable externally and upon sectioning.

**LYMPHORETICULAR SYSTEM:** The spleen is covered by a smooth, blue-gray, intact capsule. The parenchyma is dark red. The cervical, hilar, and peritoneal lymph nodes are unremarkable.

**MUSCULOSKELETAL SYSTEM:** See previous description. The clavicles and pelvis have no fractures. The diaphragm is intact.

## **TOXICOLOGY:**

### **Evidence Submitted:**

The following items were received by the Laboratory from Forensic Pathology:

- 007-008: Skeletal muscle - plastic tube
- 007-007: Vitreous - red top tube
- 007-006: Urine - red top tube
- 007: Biohazard Bag
- 007-005: Blood, femoral - red top tube
- 007-001: Blood, femoral - gray top tube
- 007-004: Blood, femoral - gray top tube
- 007-002: Blood, femoral - gray top tube
- 007-003: Blood, femoral - gray top tube



Case: IFS-15-08020 - CC

Russell, Charles Wayne

**Blood, postmortem**

**Acid/Neutral Screen (GC/MS)**  
negative (Item# 007-004)

**Alcohols/Acetone (GC)**  
negative (Item# 007-003)

**Alkaline Screen (GC/MS)**  
negative (Item# 007-003)

**Marihuana/Cannabinoids (LC/MS)**  
tetrahydrocannabinol: 9.9 ng/mL (Item# 007-003)  
carboxytetrahydrocannabinol: 41.9 ng/mL (Item# 007-003)

**Vitreous**

**Alcohols/Acetone (GC)**  
negative (Item# 007-007)

**Electrolytes (Analyzer)**  
sodium: 137 mEq/L (Item# 007-007)  
potassium: 10.9 mEq/L (Item# 007-007)  
chloride: 119 mEq/L (Item# 007-007)  
glucose: <15 mg/dL (Item# 007-007)  
urea nitrogen: 18 mg/dL (Item# 007-007)



**FINDINGS:**

## 1. Gunshot wound of chest:

- a. Entrance: right side of chest.
- b. Path: perforation of sternum, heart, aorta, right lung, eighth thoracic vertebra, and right ninth rib.
- c. Exit: right side of back.
- d. Recovery: medium caliber bullet recovered from clothing adjacent to exit wound.
- d. Directions: front to back and downward.
- e. Range of fire: no firearm residue on skin.

## 2. Blunt force injuries:

- a. Lacerations, abrasions and contusions of scalp.
- b. Abrasion of chin.
- c. Abrasions of extremities.

## 3. Remains positively identified by fingerprint comparison.

4. History that decedent and companion cases IFS-15-08016, IFS-15-08017, IFS-15-08018, IFS-15-08019, IFS-15-08021, IFS-15-08022, IFS-15-08023, and IFS-15-08029, were involved in a gun battle between rival motorcycle gangs which also involved police.

**CONCLUSIONS:**

It is our opinion that Charles Wayne Russell, a 46-year-old white male, died as a result of a gunshot wound of the chest.

**MANNER OF DEATH:** Homicide

06/30/2015


Jill E Urban, M.D.  
Medical Examiner

07/01/2015

Chester S Gwin, M.D.  
Medical Examiner




**COPY**  
DALLAS COUNTY  
INSTITUTE OF FORENSIC SCIENCES




06/30/2015

Emily Ogden, M.D.  
Medical Examiner



07/01/2015

Elizabeth Ventura, M.D.  
Medical Examiner




07/01/2015

Stephanie Burton, M.D.  
Medical Examiner




07/01/2015

Tracy J Dyer, M.D., J.D.  
Medical Examiner



07/07/2015

Janis K Townsend-Parchman, M.D.  
Medical Examiner



06/30/2015

Candace Schoppe, M.D.  
Medical Examiner



07/01/2015

Reade A Quinton, M.D.  
Deputy Chief Medical Examiner





COPY

DALLAS COUNTY  
INSTITUTE OF FORENSIC SCIENCES



06/30/2015

Jeffrey J Barnard, M.D.

Director and Chief Medical Examiner



THE SOUTHWESTERN INSTITUTE OF FORENSIC SCIENCES  
AT DALLAS

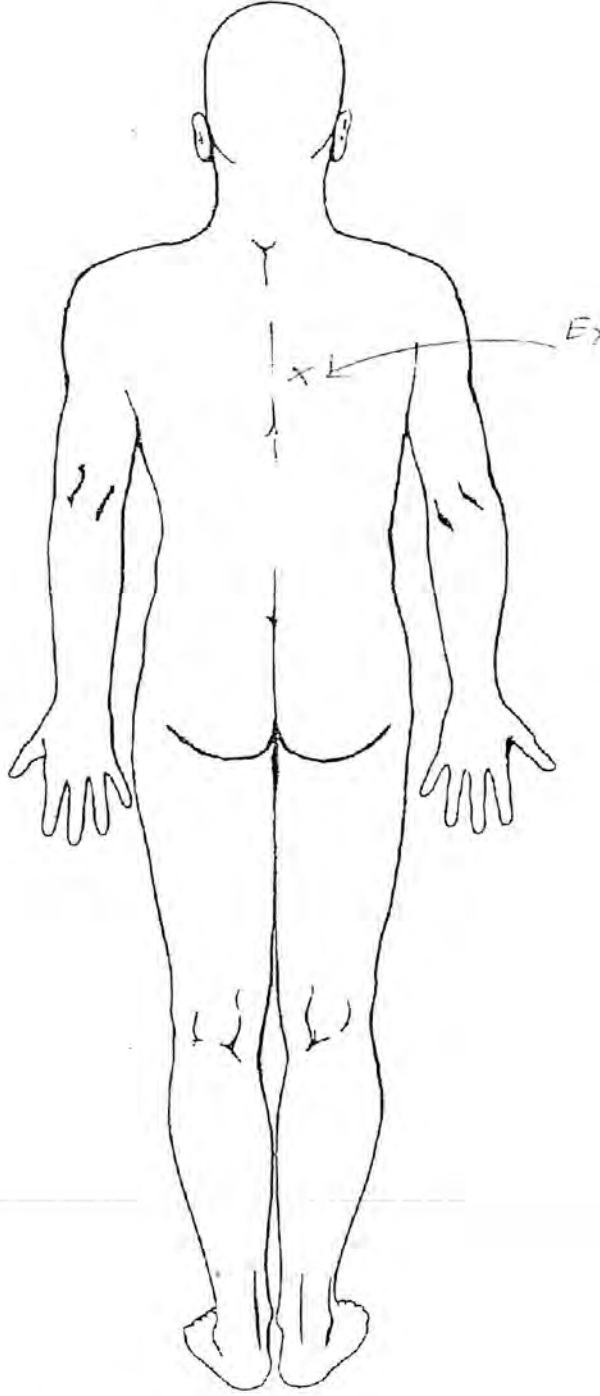
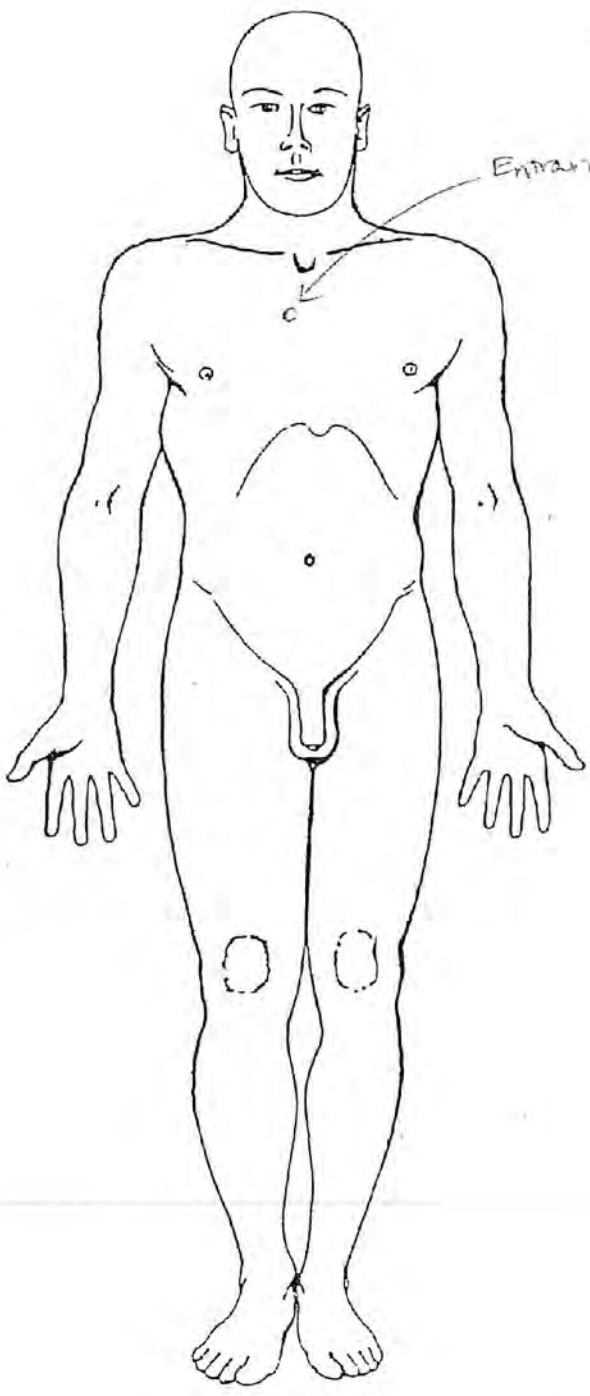
COP  
DALLAS COUNTY  
INSTITUTE OF FORENSIC S

Name Russel, Charles Wayne

Case No. 15-08020

Age \_\_\_\_\_

Date 5-18-15



Gunshot Wound of Chest

For report only